

REVISITING THE HISTORY OF TAKAYASU DISEASE: STUDIES AND SURGICAL TREATMENT

Shavkat I. Karimov², Akmal A. Irnazarov², Abdurasul A. Yulbarisov¹, Khojiakbar K. Alidjanov¹, Viktoriya E. Tsay^{2*}, Eldor M. Mirkomilov², Elnora R. Djuraeva²

1 Republican Specialized Center of Surgical Angioneurology, Tashkent, Uzbekistan

2 Tashkent Medical Academy, Uzbekistan

*E-mail: victoria-tsay@mail.ru

ABSTRACT

Nonspecific aortoarteritis (Takayasu disease) is a systemic disease belonging to the group of vasculitis, mainly affecting the arteries of the elastic and muscular-elastic types of large and medium caliber with localization of the inflammatory process in the media and adventitia. The article describes the history of the development of ideas about clinical manifestations, morphological changes and the course of the disease from 1761 to the present, the chronology of medical achievements in the study of this disease.

Key words: Takayasu disease, Nonspecific aortoarteritis, vasculitis.

INTRODUCTION

Nonspecific aortoarteritis, or Takayasu arteritis (TA), is a systemic disease belonging to the group of vasculitis with a predominant lesion of large and medium-caliber elastic and muscular-elastic arteries. TA is characterized by a chronic inflammatory process in the wall of the aorta and large arteries [73]. The inflammatory process is localized in the media and adventitia. The lesion of the intima is secondary, reactive-hyperplastic in character. Occlusive lesions of the arterial pool in patients with TA lead to the development of ischemia of the corresponding organ.

In the literature, this disease, until the mid-1970s, was most often encountered under the following terms: "pulseless disease", "arteritis of young women", "brachiocephalic arteritis", "atypical coarctation of the aorta", "Martorell's syndrome", or "syndrome of obliteration of supra-aortic trunks", "panaortitis" or

"panarteritis", "aortitis syndrome", "syndrome of the middle part of the aorta", "occlusive thromboarteriopathy" [5, 22, 27, 40, 43, 44, 85].

In the Russian literature, the name nonspecific aortoarteritis took place, since the disease is characterized by a chronic inflammatory process of the aortic wall and arteries.

History of the Study.

The history of the study of nonspecific aortoarteritis takes us back to the middle of the 18th century. According to V. Di Giacomo, J. Margagni described the first observation of nonspecific aortoarteritis in 1761, who reported autopsy findings in a 40-year-old woman with thickening and narrowing of the descending thoracic aorta and myocardial hypertrophy [16]. F. Numano and T. Kakatu believe that the first clinical case of Takayasu's arteritis was published in Japan by Rukushi Yamamoto, who observed a 45-year-old patient with a prolonged fever. A year later, the pulsation on her right arm disappeared, after that in the projection of the carotid arteries, and 11 years after the initial examination, the patient died suddenly due to shortness of breath. F. Numano and T. Kakatu quote from R. Yamamoto's monograph-diary, which was published in Japanese in 1830 [51].

In European literature in 1835, Schlesinger described a stenosing lesion of the descending aorta in a 15-year-old girl. In this patient, who died of heart failure, the supradiaphragmatic portion of the aorta was severely narrowed. Above the constriction, there was an aneurysmal expansion of the aorta, and below the diaphragm, the aorta had a normal diameter [74]. In 1856, D. Savori also published the observation "A case of a young woman in whom the main arteries of both upper extremities and of the left side of neck were throughout completely obliterated", in which he reports on stenosis of the branches of the aortic arch in a young woman who suffered from a thoracic aortic aneurysm [71]. In 1911 L.H. Hasler cites autopsy data from a patient who had narrowing of the aorta above the diaphragm. The aorta was a 7 mm fibrous cord with a length of 2.5 cm [30]. M. Hahn in 1933 observed a patient who died as a result of a hypertensive crisis; an autopsy revealed a narrowing of the aorta up to 3 mm at the level of the diaphragm [28].

True interest in nonspecific aortoarteritis arose at the beginning of the last century, when the Japanese professor of ophthalmology from the city of Kanazawa Mikito Takayasu (Fig.1.) at the XII conference of the Japanese Ophthalmological Society, held in 1908 in Fukuoka, made a report on unusual changes in the vessels retina in a 21-year-old girl suffering from syncope [83].

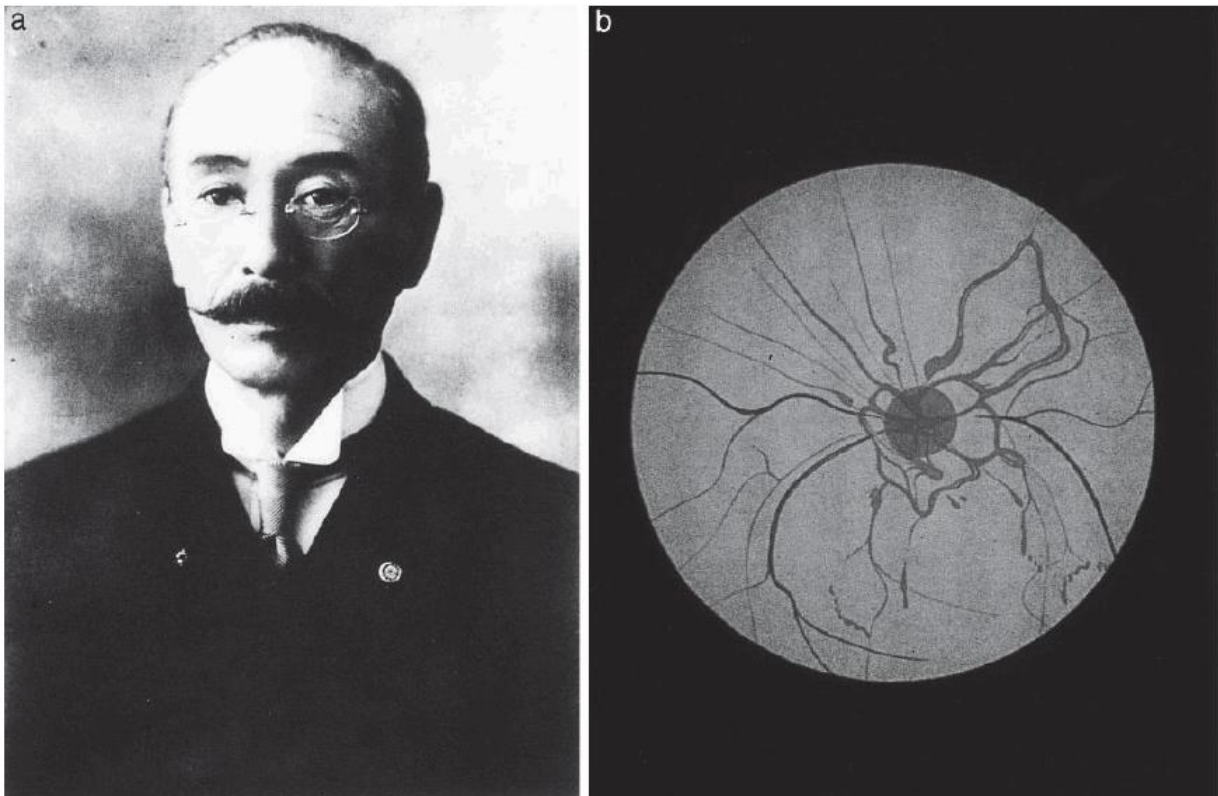


Figure 1. Japanese ophthalmologist professor Mikito Takayasu (photo a) published an observation of changes in the arteries of the retina (photo b) in combination with the absence of a pulse in the radial artery in a 21-year-old woman complaining of decreased vision.

These changes were characterized by arteriovenous fistulas in the fundus around the optic nerve papilla, visually resembling anastomoses between the coronary arteries. At the same conference, two other ophthalmologist professors K. Onishi from the University of Kyushu and Ts. Kagoshima of Kumamoto University made two similar observations, with Onishi finding no pulse in both radial arteries, and Kagoshima finding no pulse in the left radial artery. After that, the disease began to be interpreted as "the disease of the absence of a pulse." The term Takayasu arteritis was first used in Japan by Y. Sinmi in 1942 [79]. Considering that Takayasu did not notice changes in the pulsation in the hands of his patient, some doctors suggested subsequently calling this disease not Takayasu disease, but Takayasu-Onishi disease. In the English-language literature, the first to recall Takayasu's report in 1952 were American researchers W. Caccamise and J. Whitman, publishing their own observation of a patient with "no pulse disease" [10]. A R. Judge in 1962, before elucidating the etiology of the disease, suggested calling this pathology a "disease" or "Takayasu arteritis" [37], a name that has become firmly established in the English-language literature.

Until the early 1950s. in the literature there are only a few reports concerning the clinic, pathological anatomy and etiology of this disease. In 1939, T. Okabayashi cites the observation of a 28-year-old woman who was admitted to the

Department of Psychiatry at the University of Tokyo [50]. The patient had epileptic seizures and syncope, while clinically she had no pulse in both radial arteries and no pulsation was detected in the projection of the carotid arteries. A week after hospitalization, the patient died from increasing heart failure. Later, Kunio Gohta, having re-examined the autopsy material, revealed inflammatory changes in the intima and adventitia, which he called panarteritis. In addition, he found similar changes not only in the aorta, but also in the pulmonary artery. This work was the first documented study of the involvement of the aorta and its main branches in the inflammatory process [55].

In 1951, in an article entitled "Pulseless disease" R. Shimizu and K. Sano, surgeons at the University of Tokyo, summarized the experience of 25 cases published from 1908 to 1948 in Japan and reported 6 of their own observations. In this article, the authors provided a detailed description of the clinical picture of the so-called. "pulseless disease", which included a triad of symptoms: the absence of a pulse on the arm, "coronary" anastomoses in the fundus, and an increased carotid sinus reflex [77].

In 1951, Norwegian authors A. Frovig and A. Locken reported on bilateral obliteration of the carotid arteries in a young patient and cited 4 similar observations described in the literature. The authors identified symptoms characteristic of this disease: impaired cerebral circulation, changes in the fundus of the eye, muscle atrophy on the face, absence of pulsation in the arms and in the projection of the carotid arteries, and increased pressure on the lower extremities [21]. In 1953, R. Ross and V. McKusick from Baltimore cited more than 100 cases of pulselessness in the arms and neck described in the literature and called this disease "aortic arch syndrome" [65]. If the first clinical observations concerned mainly patients with a classic picture of damage to the branches of the aortic arch, then in the early 1950s reports began to appear about an inflammatory disease of the thoracic and suprarenal aorta of unknown etiology.

In 1951 L.J. Adams et al. published 2 observations of hypertensive patients with renal artery stenosis. In one case, in a 27-year-old patient, the authors apparently dealt with Takayasu's arteritis [2]. In 1959 T.J. Danaraj and W.H. Ong described 2 clinical cases of bilateral renal artery stenosis in children 7 and 12 years old, caused by arteritis. Patients died from heart failure [13]. The authors found that the process in the aorta and renal arteries resembled the changes found in the brachiocephalic arteries in Takayasu's disease. Bilateral stenoses of the renal arteries subsequently received the name of Denerey's syndrome.

In 1959-1960 there were reports of atypical coarctation of the aorta of abdominal localization in children suffering from arterial hypertension, often

resulting in the death of young patients [70, 75]. In 1960, S. Kimoto reported a case of inflammatory coarctation of the thoraco-abdominal aorta [40], and in 1963, K. Inada et al. described 10 observations of combined lesions of the branches of the aortic arch and its thoracoabdominal department [30]. It was after these publications that it became obvious that in Takayasu's disease, the stenotic process in the brachiocephalic arteries can be combined with lesions of the thoracic aorta and renal arteries. Independently of each other in 1957, several authors published observations of Takayasu disease, in which they provided a detailed description of the clinical picture of this disease [1,18].

Prevalence

In the early years of studying nonspecific aortoarteritis, it was believed that this rather rare disease occurs only in residents of eastern countries, and primarily in Japan, India and China. In 1954, E. Asp-Upmark published an article on the "pulseless disease" outside of Japan, in which he cited observations of nonspecific aortoarteritis in the Scandinavian countries [5]. Modern studies show that Takayasu's disease occurs everywhere, but the true incidence varies in different regions in a very significant range [72].

One of the first epidemiological studies conducted by S. Restrepo showed that Takayasu's disease is not at all such a rare disease. According to 22,000 autopsies, the frequency of nonspecific aortoarteritis in different countries was as follows: in the USA - 0.11%, in Puerto Rico - 0.65%, in Mexico - 2.27%, in Norway - 0.27%; on average, it was the cause of death in 0.61% of cases [66].

However, clinical and post-mortem studies conducted in subsequent years did not confirm such a high incidence of TA. Thus, the incidence of Takayasu's disease in Kuwait is 2.2 people, and in Turkey 3.4 people per million [8, 19, 69], in the UK in the population of people under 40 years of age, the frequency does not exceed 0.3 observations per million inhabitants [87]. In the USA and Scandinavian countries, the incidence rate ranges from 2.6 to 6.4 cases per million [17, 29, 45, 86]. The authors from Norway note a high frequency of detection of Takayasu's disease: 22 cases per million inhabitants, while the authors emphasize that among the cases, people from Asia and Africa were much more common [26]. According to A. Rose and P. Sinclair-Smith (2020), the incidence of the disease according to autopsy materials over a 26-year period was 0.09% [64]. Based on a study of more than 200 thousand autopsies in Japan, it was found that the incidence of nonspecific aortoarteritis in this country was 0.033% of all autopsies performed [46]. It is precisely because of the rarity of pathology in the literature for a long time there were no large statistical data, and most authors cited only single observations.

Natural Course and Possibilities of Conservative Therapy.

Literature data concerning the natural course of TA and the long-term results of its conservative treatment are very contradictory. This is primarily due to the fact that over the past 30 years, in patients with an established diagnosis of TA, various methods of conservative treatment have been used, including, as a rule, hormonal therapy, antibiotic treatment, and, in recent years, cytostatics.

K. Sano provides data on 62 patients with nonspecific aortoarteritis in Japan, 17 (25.4%) of whom died during 21 years of follow-up [68].

According to Indian researchers, after 20 years from the moment the disease was diagnosed, about 20% of patients remain alive in a natural course [81]. S. Morooka et al., observing 64 patients for 15 years, found that 62% of patients died within 10 years, and after 15 years the mortality rate was 82% [46].

Aeschlimann F.A., after conducting a summary analysis of the literature, found that out of 261 non-operated patients, 26% died, and half of them were under the age of 30 years. Most complications occur in the first years of the disease, which is associated with insufficient adaptation of patients to altered hemodynamic conditions, as well as with the aggressive development of the pathological process. So, during the 10-year period of observation of patients, 30% of patients had an acute violation of cerebral circulation, and 40% of patients had other severe complications. Cerebral complications (hemorrhagic and ischemic strokes), as well as acute heart failure, dominated among the causes of death [3].

A detailed study of the survival of patients with the natural course of TA was carried out in Japan by K. Ishikawa et al. [34]. It was based on the results of observation of 120 patients for up to 34 years (mean 13 years). Survival over the 15-year period after the diagnosis of the disease was 82.9%. Analysis of various clinical factors showed that the following factors played the most important role: arterial hypertension, retinopathy, aortic regurgitation, and the presence of aortic aneurysm. Thus, the 15-year survival rate in the group of patients who had even one of these factors was 66.3%, while in patients without risk factors it was 96.4%. In patients with ongoing inflammation, the survival rate was lower and amounted to 67.2%, while in cases with low activity of the inflammatory process and without relapses, it was 92.9% [34].

Arterial hypertension is one of the most unfavorable factors according to a number of researchers. Thus, according to I. Ito, among the deceased patients, complications of renovascular hypertension were the cause of death in more than half of the cases [35]. C. Comarmond et al. cite data from a multicenter study that examined prognostic factors and complication rates among 318 patients with Takayasu's disease [12]. Disease progression was detected in 45% of cases.

Unfavorable factors affecting the level of mortality and the occurrence of severe complications are damage to the renal arteries and thoracoabdominal aorta, the activity of the inflammatory process and retinopathy [12].

According to H. Ogino, progression and vascular complications occur in 50% of patients within 10 years [54]. It has been established that the most often unfavorable outcomes occur with V-type lesions (total damage to the branches of the aortic arch, thoracic and abdominal aorta with visceral and renal arteries) according to the Hata classification [42, 58, 80]. Another unfavorable factor is ongoing inflammation during or after revascularization. The study of the development of the frequency of complications showed a direct correlation of thrombosis with the level of ESR, an increase in C-reactive protein and the level of fibrinogen [67]. Rapid withdrawal of hormones also statistically significantly increases the frequency of relapses [53]. The latter often occur in the first 5 years after diagnosis. C. Comarmond et al. revealed that the first recurrence of inflammation in these terms occurs in 42% of patients, and in 20% in the first year. Elimination of inflammatory markers and achievement of stable remission is the most important task of conservative treatment [37, 47]. There is evidence of higher mortality and worse outcomes of surgical treatment in male patients. Thus, progression of the process or lethality within 5 years occurred in 57% of men, 38% of women [12].

The main principle of the treatment of TA is the concept that surgery and medical treatment should not be opposed to each other [38]. Conservative treatment accompanies patients before surgery, during surgery and in the postoperative period and is a complex task. It is aimed at suppressing acute inflammation in the wall of the aorta and arteries, preventing possible complications associated mainly with arterial hypertension.

With inadequate anti-inflammatory treatment, the process passes into protracted subacute stages, which leads to further progression of the disease. It should be remembered that even when clinical remission is achieved, new lesions may appear [39, 24]. With ineffective treatment, 88% of patients show progression of the disease, and more than 61% of cases develop lesions of the aorta and main arteries in places previously intact from inflammation [39]. Noteworthy is the message of R. Pajari et al., who was one of the first to show the relationship between the results of surgical treatment and ongoing inflammation. According to his data, in patients with inflammation, the patency of the reconstructed arteries during the observation period up to 3 years was only 53%, while in patients operated on in the chronic stage of the disease, it was 88% [56].

For a long time in the medical community, disputes about ways to stop the inflammatory process in the wall of the aorta and its branches did not subside. In actual clinical practice, various treatments have been used, ranging from treatment with corticosteroids [46] and anti-tuberculosis drugs [11, 41] to herbal and acupuncture [78] and even progesterone therapy [52].

Yudin V.I., following the long-term results of the use of pulse therapy in 32 patients for 36 months, noted that only 13 (41%) patients had no relapses of inflammation, while the remaining 19 (59%) patients 34 recurrences of the inflammatory process were noted during 3 years of follow-up [62]. The studies also showed that morphological remission occurs later (3-4 months after stable normalization of laboratory parameters) than clinical. Thus, 10 patients were operated immediately after completion of the course of pulse therapy. Histologically revealed ongoing inflammation in the aortic wall in 7 patients. In all 17 patients operated after 3-4 months after successful completion of the course of pulse therapy, the morphological picture corresponded to the chronic stage of inflammation.

Tanigawa K., on the basis of ultrasound data performed in the long term after pulse therapy, it was proved that the normalization of clinical and laboratory parameters is accompanied by a decrease in the thickness of the artery wall. A similar regression of the degree of stenosis under the influence of anti-inflammatory therapy according to MRI and CTA data was also observed by other researchers [4, 32, 84].

In recent years, there have been new approaches to the treatment of the active stage of nonspecific aortoarteritis. Its further prospects are associated with genetically engineered biological preparations (immunocorrectors), the use of which creates the basis for personalized therapy for Takayasu's disease. Data have appeared on the successful use of tumor necrosis factor- α inhibitors (infliximab) [25, 49] and interleukin 6 inhibitors (tocilizumab) in some patients with glucocorticosteroid-resistant aortoarteritis [48].

Surgical Treatment

The era of TA surgical treatment dates back to the late 1940s and early 1950s. 20th century In 1951, Japanese researchers K. Shimizu and K. Sano reported the first successful interventions on the branches of the aortic arch [77]. Surgical concepts and ideas changed, transthoracic interventions were replaced by extrathoracic operations. The tempting idea of simultaneous reconstruction of both carotid arteries did not justify itself, since these operations significantly increase the risk of hemorrhagic stroke. Therefore, one-stage bicarotid reconstructions were

replaced by surgeries with gradual inclusion of the carotid arteries into the bloodstream [72].

One of the most difficult sections of the surgical treatment of TA is operations on the thoracoabdominal aorta, visceral and renal arteries. In the literature, the priority of the first operations on the thoracoabdominal aorta is given to surgeons from Baltimore. In 1949 H.T. Bahnson et al. published 2 observations. The first case involved surgery on a 35-year-old woman with high aortic occlusion. In 2 cases, a 17-year-old girl had a narrowing located immediately above the renal arteries, while the patient had severe arterial hypertension. The authors did not dare to perform a reconstructive intervention and limited themselves to arterial denervation of the renal vessels and omentopexy of the constriction zone [6].

Almost all the first publications concerning the surgical treatment of stenotic lesions of the thoracic aorta and renal arteries were interpreted in the literature of those years as atypical coarctation of the aorta, and only after the publication of S. Kimoto in 1960 and K. Inada in 1963, atypical coarctation with damage to the renal arteries began to be associated with Takayasu's disease. Today's views make it possible to convincingly interpret these first operations in patients with atypical coarctation as in patients suffering from TA [33].

In 1951 E.J. Beattie published an observation of surgical treatment in a 19-year-old girl suffering from arterial hypertension. Angiography revealed narrowing of the aorta just below the diaphragm. In this regard, the authors performed a resection of the narrowed area with prosthetics with a homograft. By the time of discharge, the patient noted a decrease in blood pressure [7].

In 1952, F. Glenn was the first to use the distal part of the splenic artery as a shunt, performing, in fact, bypassing the narrowed suprarenic thoracic aorta through the celiac trunk [23].

In 1953, the New York surgeon R.A. Deterling et al. In 1991, a case was published in which the authors performed a resection of the supradiaphragmatic part of the thoracic aorta with prosthesis with a homograft in a 23-year-old woman of Puerto Rican origin [15].

The first successful simultaneous reconstruction of an atypical coarctation and renal artery was performed on a 12-year-old girl by surgeons from the University of Washington J.M. Stokes et al. in 1960 [82]. The same patient underwent aorto-right renal bypass grafting at the second stage.

In 1964, the Swedish surgeons V. Bjork and F. Intonti, having studied the literature, collected 26 cases of atypical coarctation located in the supra- and subphrenic part of the aorta. In 12 cases, reconstructive operations were performed, 9 of which were successful. The authors themselves reported an observation of an

18-year-old girl with stenosis of the supra- and subdiaphragmatic part of the aorta in combination with stenosis of the right renal artery. This patient underwent successful aorto-aortic bypass and aorto-right renal bypass (Fig. 2) [9].

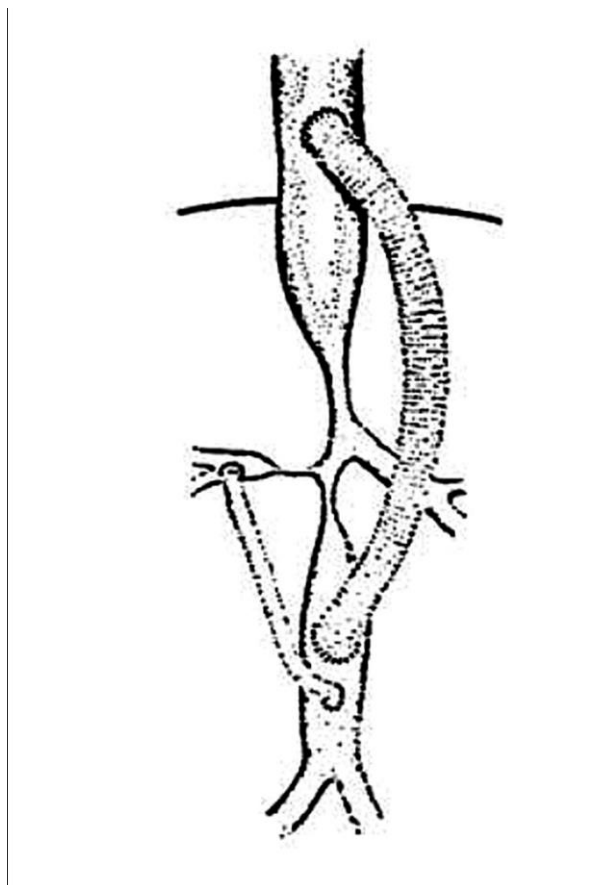


Figure 2. Surgery diagram according to V. Björk and F. Intonti (1964), aorto-aortic bypass grafting, right renal artery replacement

The authors noted extremely poor follow-up of 14 non-operated patients. Their average life expectancy was 30 years. The following year, F. Robicsec et al. publish literature data on 33 patients with atypical coarctation and cite 3 own observations [63].

In 1967 M.E. DeBakey et al. publish the first major statistics of reconstructive surgery, which includes 26 patients with atypical coarctation, of which 16 patients, aged 6 to 41 years, had combined stenotic lesions of the thoracoabdominal aorta and renal arteries. In all cases, bypass surgery with reconstruction of the renal arteries was performed. A brilliant result was obtained. There were no lethal outcomes among the operated patients, in 15 cases a stable hypotensive effect was achieved. In a 7-year-old patient, a left-sided nephrectomy had to be performed to correct pressure due to developed renal artery thrombosis [14].

In Russia, the first successful reconstructive operation was performed by B.V. Petrovsky in 1961 in a 14-year-old boy with stenosis of both renal arteries. This patient underwent a mesenteric-renal anastomosis on the right [60]. In 1962, A.V.

Pokrovsky was the first in the world to use the thoracophrenolumbotomy developed by him to approach the thoracoabdominal aorta, visceral and renal arteries. This access abroad was called "Russian access" [72]. In 1971 A.V. Pokrovsky et al. the operation of transaortic endarterectomy from the thoracoabdominal aorta and its branches was developed and put into practice. This technique made it possible to successfully restore blood flow in the aorta, visceral and renal arteries in patients with fibrotic changes in the vessel wall [61].

In 1960-1970. in the department of ISSH them. A.N. Bakuleva is rapidly accumulating experience in the surgical treatment of this disease. This becomes possible because patients from all far corners of the USSR begin to concentrate in the department. Already in 1991, A.V. Pokrovsky publishes the results of surgical treatment of 303 patients, which at that time was the world's largest experience in the surgical treatment of such patients [29].

The development of endovascular technologies, good immediate results and low invasiveness have made it possible to use these methods in the treatment of patients with Takayasu's arteritis. However, the mid-term and long-term results of endovascular operations on the carotid and renal arteries in Takayasu's disease indicate a higher risk of restenosis both after angioplasty and after stenting. Despite the lack of large comparative studies, the results of open surgery seem to be more impressive. According to most authors, the frequency of restenosis after prosthetics of the renal and carotid arteries in patients with aortoarteritis is lower than after endovascular operations. In addition, open reconstructions are more appropriate for prolonged stenoses, as well as for vascular occlusions [20].

Disputes about the need to use stents during endovascular procedures in patients with aortoarteritis do not subside among specialists. Thus, in a study published by Korean scientists, the authors argue that angioplasty without stent implantation has advantages in terms of 5-year patency and the frequency of resteno-calls in the long term after the intervention. In their study group, the rate of restenoses after angioplasty of the renal arteries was 8%, while after stenting, the rate of restenoses reached 66% [57]. Authors from India adhere to the same point of view, giving preference to primary balloon angioplasty and using stenting in case of restenosis and other complications. The 5-year renal artery patency in this study was 67% [76]. In a meta-analysis of 7 studies, which included 266 patients, it was shown that the frequency of restenoses is higher in the group of patients who underwent renal artery stenting compared with patients who underwent only angioplasty of the renal arteries. Despite this, the reduction in the level of arterial hypertension was similar in both groups, and the frequency of direct complications after surgery is higher in patients after angioplasty [36]. In a study by Chinese

scientists, the primary patency of the renal arteries was higher after balloon angioplasty compared with stenting (90.1% versus 75.6%), and the incidence of restenosis and the need for reoperations were higher in the group of patients after stenting of the renal arteries [59].

Literature data based on the analysis of long-term results of surgical and conservative treatment made it possible to identify some characteristic features of the course and the possibility of predicting the results of treatment. Over the years, there have been certain shifts: in particular, in determining the tactical issues of treating patients, heated discussions between therapists and surgeons about the advantages of the methods of treatment offered by each side are a thing of the past. In this regard, there is no doubt that the treatment of patients should be comprehensive - adequate anti-inflammatory therapy, reaching the stage of morphological remission, and only then - reconstructive intervention.

REFERENCES

1. Abugova S.P. Pulseless disease. *Clinical medicine*. 1957;35(1):112-116.
2. Adams L.J., Notkin M., Pritchard J.E. Hypertension in two cases of renal artery occlusion. *Canada M A J*. 1951;64:224
3. Aeschlimann F.A., Eng S.W.M., Sheikh S., Laxer R.M., Hebert D., Noone D. et al. Takayasu arteritis: disease course and response to therapy. *Arthritis Res Ther*. (2019) 19:255. doi: 10.1186/s13075-017-1452-4
4. Ashizawa N., Suzuki S., Kobayashi M., Aoi W., Hashiba K. A case of aortitis syndrome with severe coarctation of the aorta. *Angiology*. 2020;36(3):197-200. doi: 10.1177/000331978503600309.
5. Asp-Upmark E. On the pulseless disease outside of Japan. *Acta Med Scan*. 1954;49(3):161-178. Available at: <https://pubmed.ncbi.nlm.nih.gov/13180224/>
6. Bahnson H.T., Cooley R.N., Sloan R.D. Coarctation of the aorta at unusual sites. *Am Heart J*. 1949;38(6):905-913. doi: 10.1016/0002-8703(49)90891-1.
7. Beattie E.J. Jr., Cooke F. N., Paul J. S., Orbison J. A. Coarctation of Aorta at Level of Diaphragm Treated Successfully with Preserved Human Blood Vessel Graft *J ThoracSurg*. 1951;21(5):506-512. Available at: <https://pubmed.ncbi.nlm.nih.gov/14841786/>
8. Birlik M., Kucukyavas Y., Aksu K., Solmaz D., Can G., Taylan A. et al. Epidemiology of Takayasu's arteritis in Turkey. *ClinExpRheumatol*. 2019; 34(3Suppl 97):S33-S39. Available at: <https://pubmed.ncbi.nlm.nih.gov/26633698/>
9. Bjork V., Intonti F. Coarctation of Abdominal Aorta with Right renal artery Stenosis. *Ann Surg*. 1951;160(1):54-60. doi: 10.1097/00000658-196407000-00008.
10. Caccamise W.C., Okuda K. Takayasu's or pulseless disease. *Am J Ophthalmology*. 1954;37(4):6781-6783.

11. Chugh K.S., Jain S., Sakhuja V., Malik N., Gupta A., Gupta A. et al. Renovascular hypertension due to Takayasu's arteritis among Indian patients. *Q J Med.* 2021;85(307-308):833-843.
12. Comarmond C., Biard L., Lambert M., Mekinian A., Ferfar Y., Kahn J.E. et al. Long-term outcomes and prognostic factors of complications in Takayasu arteritis. *circulation.* 2017;136(12):1114-1122. doi: 10.1161/CIRCULATIONAHA.116.027094.
13. Danaraj T.J., Ong W.H. Primary arteritis of abdominal aorta in children causing bilateral stenosis of renal arteries and hypertension. *circulation.* 1959;20:856-863. doi: 10.1161/01.cir.20.5.856.
14. DeBakey M.E., Garrett H.E., Howell J.F. Coarctation of the abdominal aorta with renal artery stenosis: surgical considerations. *Ann Surg.* 1967;165(5):830-843. doi: 10.1097/00000658-196705000-00019.
15. Deterling R.A. Resection of an acquired coarctation of the low thoracic aorta and replacement with a preserved vessel graft. *J Thorac Surg.* 1953;26(3):290-299.
16. Di Giacomo V. A case of Takayasu's disease occurred over two hundred years ago. *Angiology.* 1984;35(11):750-754. doi: 10.1177/000331978403501111.
17. Dreyer L., Faurschou M., Baslund B. A population-based study of Takayasu's arteritis in eastern Denmark. *ClinExpRheumatol.* 2021;29(1 Suppl 64):S40-S42. Available at: <https://pubmed.ncbi.nlm.nih.gov/21385546/>
18. Dzhibladze D.N. A case of pulseless disease. *Clinical medicine.* 1957;35(1):115-117.
19. El-Reshaid K., Varro J., Al-Duwairi Q., Anim J.T. Takayasu's arteritis in Kuwait. *J Trop Med Hyg.* 2020;98(5):299-305. Available at: <https://pubmed.http://ncbi.nlm.nih.gov/7563255/>
20. Feng R., Wei X., Zhao Z., Bao J., Feng X., Qu L. et al. Aortorenal bypass with autologous saphenous vein in Takayasu arteritis-induced renal artery stenosis. *Eur J VascEndovasc Surg.* 2021;42(1):47-53. doi: 10.1016/j.ejvs.2011.03.004.
21. Frovig A.G., Loken A.C. The syndrome of obliteration of the arterial branches of the aortic arch, due to arteritis; a post-mortem angiographic and pathological study. *ActaPsychiatrNeurol Scand.* 1951;26(3-4):313-337. Available at: <https://pubmed.http://ncbi.nlm.nih.gov/14933169/>
22. Gibbons T.B., King R.L. Obliterative branchiocephalic arteritis: Pulseless disease of Takayasu. *circulation.* 1957;15(6):845. doi: 10.1161/01.cir.15.6.845.
23. Glenn F., Keefer E.B.C., Speer D.S., Dotter C.T. Coarctation of the Lower Thoracic and Abdominal Aorta Immediately Proximal to the Celiac Axis. *SurgGynec Obstet.* 1952;94:561.
24. Grayson P., Alehashemi S., Bagheri A. 18F-Fluorodeoxyglucose-Positron Emission Tomography as an imaging Biomarker in a prospective, longitudinal study of patients with Large vessel vasculitis. *Arthritis Rheumatol.* 2018;70(3):439-449. doi: 10.1002/art.40379.
25. Gudbrandsson B., Molberg O., Garen T., Palm O. Prevalence, Incidence, and Disease Characteristics of Takayasu Arteritis by Ethnic Background: Data

From a Large, Population-Based Cohort Resident in Southern Norway. *Arthritis Care Res (Hoboken)*. 2019;69(2):278-285. doi: 10.1002/acr.22931.

26. Gudbrandsson B., Molberg O., Palm O. TNF inhibitors appear to inhibit disease progression and improve outcome in Takayasu arteritis; an observational, population-based time trend study. *Arthritis Res Ther*. 2017;19(1):99. doi: 10.1186/s13075-017-1316-y.

27. Gupta S. Surgical and hemodynamic considerations in middle aortic syndrome. *Thorax*. 1979;34:470-478. doi: 10.1136/thx.34.4.470.

28. Hahn M. Zur Frage Tiefsitzender Frage tiefsitzender Stenosen der absteigenden Brusttaorta. Inaug.-Diss. Berlin; 1933

29. Hall S., Barr W., Lie J.T., Stanson A.W., Kazmier F.J., Hunder G.G. Takayasu arteritis. A study of 32 North American patients. *Medicine (Baltimore)*. 2021; 64(2):89-99. Available at: <https://pubmed.ncbi.nlm.nih.gov/2858047/>

30. Hasler L.H. Über einen Fall von Verschlufi der Aorta anungewohnter Stelle. Inaug.-Disc. Leipzig; 1911.

31. Hoffman G.S., Cid M.C., Hellmann D.B., Guillevin L., Stone J.H., Schousboe J. et al. International Network for the Study of Systemic Vasculitis. A multicenter, randomized, double-blind, placebo-controlled trial of adjuvant methotrexate treatment for giant cell arteritis. *Arthritis Rheum*. 2021;46(5):1309-1318. doi: 10.1002/art.10262.

32. Iga K., Gohma I., Hori K. Regression of the left main trunklesion by steroid administration in Takayasu's aortitis *Chest*. 2021;99(2):508-510. doi: 10.1378/chest.99.2.508.

33. Inada K., Yokoyama T., Nakaya R. Atypical Coarctation of the Aorta. *Angiology*. 1963;14:506-517. doi: 10.1177/000331976301401004.

34. Ishikawa K., Maetani S. Long-term outcome for 120 Japanese patients with Takayasu's disease. Clinical and statistical analyzes of related prognostic factors. *circulation*. 2020;90(4):855-860. doi: 10.1161/01.cir.90.4.1855.

35. Ito I. Medical treatment of Takayasu's arteritis. *Heart Vessels*. 2020;7:133-137. doi: 10.1007/BF01744559.

36. Jeong H.S., Jung J.H., Song G.G., Choi S.J., Hong S.J. Endovascular balloon angioplasty versus stenting in patients with Takayasu arteritis: a meta-analysis. *Medicine (Baltimore)*. 2019;96(29):e7558. doi: 10.1097/MD.0000000000007558.

37. Judge R.D., Currier R., Gracie W.A., Fingley M.M. Takayasu's arteritis and the aortic arch syndrome. *Amer J Med*. 1962;32(3):379-392. doi: 10.1016/0002-9343(62)90128-6.

38. Keiffer E., Piquois A., Bertal A., Bletry O., Godeau P. Reconstructive surgery of the renal arteries in Takayasu's disease. *Ann Vasc Surg*. 2020;4(2):156-165. doi: 10.1007/BF02001372.

39. Kerr G.S., Hallahan C.W., Giordano J., Leavitt R.Y., Fauci A.S., Rottem M., Hoffman G.S. Takayasu arteritis. *Ann Intern Med*. 2020;120(11):919-929. doi: 10.7326/0003-4819-120-11-199406010-00004.

40. Kimoto S. Surgical treatment of coarctation of the aorta with special reference to atypical coarctation. *ClinSurg (Jap)*. 1960;5:15.
41. Kinare S.G. Nonspecific aortitis (Takayasu's disease). *PatholMicrobiol (Basel)*. 2019;43(2):134-139. doi: 10.1159/000162808.
42. Lee G.Y., Jang S.Y., Ko S.M., Kim E.K., Lee S.H., Han H. et al. Cardiovascular manifestations of Takayasu arteritis and their relationship to the disease activity: analysis of 204 Korean patients at a single center. *Int J Cardiol*. 2008;159(1):14-20. doi: 10.1016/j.ijcard.2011.01.094.
43. Mackawa M., Ishikawa K. Occlusive thromboaropathy. *Jap Circ*. 1996;30:79.
44. Martorell F. The syndrome of occlusion of the supra-aortic trunks. *J Cardiovasc Surg*. 1961;2:291. Available at: <https://www.semanticscholar.org/paper/The-syndrome-of-occlusion-of-the-supraaortic-Martorell/af26e50233bf1f725a3721053f93ed06a58890b1>.
45. Mohammad A.J., Mandl T. Takayasu arteritis in southern Sweden. *J Rheumatol*. 2021;42(5):853-858. doi: 10.3899/jrheum.140843.
46. Morooka S., Ito I., Yamaguchi H., Takeda T., Saito Y. Follow-up observation of aortitis syndrome. *Jpn Heart J*. 2021;13(3):201-213. doi: 10.1536/ihj.13.201.
47. Mukhtyar C., Guillevin L., Cid M.C., Dasgupta B., de Groot K., Gross W. et al. European Vasculitis Study Group. EULAR recommendations for the management of large vessel vasculitis. *Ann Rheum Dis*. 2021;68(3):318-323. doi: 10.1136/ard.2008.088096.
48. Nakaoka Y., Isobe M., Takei S., Tanaka Y., Ishii T., Yokota S. et al. Efficacy and safety of tocilizumab in patients with refractory Takayasu arteritis: results from a randomised, double-blind, placebo-controlled phase 3 trial in Japan (the TAKT study). *Ann Rheum Dis*. 2018;77(3):348-354. doi: 10.1136/annrheumdis-2017-211878.
49. Novikov P.I., Smitienko I.O., Moiseev S.V. Tumor necrosis factor alpha inhibitors in patients with Takayasu's arteritis refractory to standard immunosuppressive treatment: cases series and review of the literature. *ClinRheumatol*. 2019;32(9):1827-1832. doi: 10.1007/s10067-013-2380-6.
50. Numano F. The story of Takayasu arteritis. *Rheumatology*. 2002;41(1):103-106. doi: 10.1093/rheumatology/41.1.103.
51. Numano F., Kakuta T. Takayasu arteritis-five doctors in the history of Takayasu arteritis. *Int J Cardiol*. 1996;54(Suppl. 1):S1-S10. doi: 10.1016/0167-5273(96)02680-0.
52. Numano F., Sagara A., Hunado V. Progesterone treatment of Takayasu's disease. *Jap Circ J*. 2019;38(7):620-625.
53. Ohigashi H., Haraguchi G., Konishi M., Tezuka D., Kamiishi T., Ishihara T., Isobe M. Improved prognosis of Takayasu arteritis over the past decade: a comprehensive analysis of 106 patients. *Circ J*. 2021;76(4):1004-1011. doi: 10.1253/cirg.g-11-1108.

54. Ogino H., Matsuda H., Minatoya K., Sasaki H., Tanaka H., Matsumura Y. et al. Overview of late outcome of medical and surgical treatment for Takayasu arteritis. *circulation.* 2018;118(25):2738-2747. doi: 10.1161/CIRCULATIONAHA.107.759589.
55. Oohta K. Einseltener Fall von beiderseitigem Carotis Subclaviaverschluss (Ein Beitrag zur Pathologie der anastomosis peripapillaris des Auges mit Fehlendem Radialpuls). *Trans Soc Pathol Jap.* 1940;30:680-690.
56. Pajari R., Hekali P., Harjola P.T. Treatment of Takayasu's arteritis: an analysis of 29 operated patients. *Thorac Cardiovasc Surg.* 2019;34(3):176-181. doi: 10.1055/s-2007-1020404.
57. Park H.S., Do Y.S., Park K.B. et al. Long term results of endovascular treatment in renal arterial stenosis from Takayasu arteritis: angioplasty versus stent placement. *Eur J Radiol.* 2020;82(11):1913-1918. doi: 10.1016/j.ejrad.2013.06.019.
58. Park M.C., Lee S.W., Park Y.B., Chung N.S., Lee S.K. Clinical characteristics and outcomes of Takayasu's arteritis: analysis of 108 patients using standardized criteria for diagnosis, activity assessment, and angiographic classification. *Scand J Rheumatol.* 2021;34(4):284-292. doi: 10.1080/03009740510026526.
59. Peng M., Ji W., Jiang X., Dong H., Zou Y., Song L. et al. Selective stent placement versus balloon angioplasty for renovascular hypertension caused by Takayasu arteritis: two-year results. *Int J Cardiol.* 2021;205:117e23. doi: 10.1016/j.ijcard.2015.12.006.
60. Petrovsky B.V., Krylov V.S., Krotovsky V.S. On the surgical treatment of "pulseless disease" (Takayashi's syndrome). *Bulletin of Surgery.* 1962;(4):28-35.
61. Pokrovsky A.V., Tsireshkin D.M., Rabotnikov V.S. etc. Nonspecific stenosing aortitis. *Thoracic surgery.* 1972;(3):97-103.
62. Pokrovsky A.V., Varava B.N., Yudin V.I., Zotikov A.E. Indications for the use of the method of pulse therapy with cyclophosphamide and 6-methylprednisolone in patients with acute and subacute nonspecific aortoarteritis. *Surgery.* 2017;(12):35-39.
63. Robicsek F., Sanger P.W., Daugherty H.K. Coarctation of Abdominal Aorta Diagnosed by Aortography: Report of Three Cases. *Ann Surg.* 1965;162(2):227. doi: 10.1097/00000658-196508000-00009.
64. Rosse A.G., Sinclair-Smith P. Takayasu's arteritis. A study of 16 autopsy cases. *Arch Pathol Lab Med.* 2020;104(5):231-237. Available at: <https://pubmed.ncbi.nlm.nih.gov/6102853/>
65. Ross R.S., McKusick V.A. Aortic arch syndromes: diminished or absent pulses in arteries arising from the arch of the aorta. *AMA Arch Intern Med.* 1953;92(5):701-740. doi: 10.1001/archinte.1953.00240230101011.
66. Restrepo C., Tejada C., Correa P. Nonsyphilitic aortitis. *Arch Path.* 2021;87(1):1-13. Available at: <https://pubmed.ncbi.nlm.nih.gov/5782433/>
67. Saadoun D., Lambert M., Mirault T., Resche-Rigon M., Koskas F., Cluzel P. et al. retrospective analysis of surgery versus endovascular intervention in

Takayasu arteritis: a multicenter experience. *circulation*. 2022;125(6):813-819. doi: 10.1161/CIRCULATIONAHA.111.058032.

68. Sano K., Aibo T. Pulseless disease: Summary of our 62 cases. *Jap Circ J*. 2021;30(1):63-67.

69. Saritas F., Donmez S., Direskeneli H., Pamuk O.N. The epidemiology of Takayasu arteritis: a hospital-based study from northwestern part of Turkey. *Rheumatol Int*. 2019; 36(7):911-916. doi: 10.1007/s00296-016-3445-z.

70. Sato T. et al. Hypertension Caused by Inflammatory Stenosis of the Aorta: Report of a Child Case. *Int Med Pediat (Jap)*. 1958;13:615.

71. Savory D. Case of a young woman in whom the main arteries of both upper extremities and of the left side of neck were throughout completely obliterated. *Med Chir Trans*. 1856;39:205-219. Available at: <https://pubmed.ncbi.nlm.nih.gov/20896061/>.

72. Sekiguchi M, Suzuki J. An overview on Takayasu arteritis. *Heart Vessels* (2021) 7:6–10. doi: 10.1007/BF01744537

73. Sen P.K. Non-specific arteritis of the aorta and its main branches. *Bull SocInt Med*. 1973;32(3):129-136.

74. Schlesinger H. Merkwürdigeyerschliessung der Aorta, Casper's. *Vchnschr. f. d. ges. heilk*. 1835;31:489.

75. Shapiro M.J. Coarctation of the Abdominal Aorta. *Amer J Cardiol*. 1959;4:547.

76. Sharma S., Gupta A. Visceral artery interventions in Takayasu's arteritis. *SeminInterventRadiol*. 2019;26(3):233-244. doi: 10.1055/s-0029-1225668.

77. Shimizu K., Sano K. Pulseless disease. *J NeuropatholClin Neurol*. 1951;1(1):37-47. Available at: <https://pubmed.ncbi.nlm.nih.gov/24538949/>

78. Shi X.M., Wang C.X., Zhang C.S., Han J.X., Lu F.C., Zheng Y.H. 30 cases of "pulseless disease" treated with acupuncture. *J Tradit Chin Med*. 2018;6(4):273-276.

79. Sinmi Y. A case of Takayasu's arteritis (in Japanese). *Sogo Gannka*. 1942;36:1404-1410.

80. Soto M.E., Espinola N., Flores-Suarez L.F., Reyes P.A. Takayasu arteritis: clinical features in 110 Mexican Mestizo patients and cardiovascular impact on survival and prognosis. *ClinExpRheumatol*. 2018;26(3 Suppl 49):S9-S15. Available at: <https://pubmed.ncbi.nlm.nih.gov/18799047/>

81. Stipa S., Callavago A. (eds). Non specific aortoarteritis in India. *Peripheral Arterial Diseases medical and surgical problems*. Rome, Italy; 2021.

82. Stokes J.M., Wohltman H., Carlsson E. Coarctation of the Abdominal Aorta and Renal Artery Stenosis Corrected by Surgical Treatment. *Ann Surg*. 1960;152(5):856-860. doi: 10.1097/00000658-196011000-00011.

83. Takayasu M. A case of a peculiar change in the central retinal vessels. *ActaSocOphthalmalJpn*. 1908;12:554.

84. Tanigawa K., Eguchi K., Kitamura Y., Kawakami A., Ida H., Yamashita S. et al. Magnetic resonance imaging detection of aortic and pulmonary artery wall thickening in the acute stage of Takayasu arteritis. Improvement of clinical and

radiological findings after steroid therapy. *Arthritis Rheum.* 2021;35(4):476-480. Available at: <https://onlinelibrary.wiley.com/doi/abs/10.1002/art.1780350419>.

85. Ueda H., Morooka S., Ito I., Yamaguchi H., Takeda T., Saito Y. Clinical observation on 52 cases of aortitis syndrom. *Jpn Heart J.* 1969;10(4):277-288. doi: 10.1536/ihj.10.277.

86. Waern A.U., Andersson P., Hemmingsson A. Takayasu's arteritis: a hospital-region based study on occurrence, treatment and prognosis. *Angiology.* 2021;34(5):311-320. doi: 10.1177/000331978303400504.

87. Watts R., Al-Taiar A., Mooney J., Scott D., MacGregor A. The epidemiology of Takayasu arteritis in the UK. *Rheumatology.* 2019; 48(8):1008-1011. doi: 10.1093/rheumatology/kep153.