

## CLINICAL EXPERIENCE OF TRIPLE-NEGATIVE BREAST CANCER TREATMENT

Djakhongir R. Sabirov<sup>1</sup>, Petr Y. Ignatov<sup>2</sup>, Oybarchin J. Yusupova<sup>3</sup>

1 DSc, PhD, Docent at Tashkent Medical Academy, Uzbekistan.  
E-mail: jrsabirov@gmail.com

2 Doctor of Biological Sciences, Professor, Director IGN-international 2 Bella Firenze, CA, 92532, USA, consulting professor at Tashkent Research Institute of Vaccines and Serums.  
E-mail: ignatovpeter@gmail.com

3 Master student of the Department of Medical Radiology,  
Tashkent Medical Academy, Uzbekistan.

### ABSTRACT

The authors have demonstrated a successful case of treating a patient by using an optimized approach to immunological correction in the course of oncolytic therapy. Treatment began with the correction of the immune system using nonspecific immunomodulatory agents and methods. Afterwards, a course of oncolytic therapy (chemotherapy) was carried out, and at first full doses of cytostatic drugs were used, and then their dosages were lowered. At the end of the course of chemotherapy, it is recommended to use drugs that suppress the processes of proliferative reactivation of tumor cells. The authors believe that the description of this clinical experience may be interesting in terms of searching for new approaches to the management of cancer patients.

**Key words:** triple negative breast cancer, low-dose chemotherapy, correction of the immune system in oncology, surgical rehabilitation technology

### INTRODUCTION

Breast cancer (BC) remains one of the most common diseases in women throughout the world [4] [6] [7] [9]. In 2020, breast cancer accounted for one in eight new cases of cancer worldwide and one in four among women. Breast cancer was diagnosed in 2.3 million people around the world and 685,000 died from it. In the structure of diseases amongst women in Uzbekistan, the most common are breast (24.5%), cervical (12.3%) and ovarian (6.1%) cancers. The average age of diagnosed women was 54.6 years. Only 8% of breast cancer is detected at stage I,

the stage which makes it possible to effectively treat and cure patients. Globally, triple-negative breast cancer is diagnosed in approximately 20–24% of cases of breast cancer patients [1] [5]. In women under the age of 40, breast cancer is the leading cause of death [5] [7]. The median survival rate for women with triple-negative metastatic breast cancer is less than one year [10]. For triple -negative breast cancer, a characteristic factor is the complete absence of receptors on cancer cells to estrogen, progesterone and epidermal growth factor [1] [3].

We demonstrate the first successful case of an optimized treatment approach [8,11] for triple-negative breast cancer in a young patient. Clinical case: Patient N.S., 41 years old, was treated from April to September 2021 with a diagnosis of breast cancer. Triple Negative; T3N1M0. From the anamnesis: Patient N.S. sick since August 2020. She associates her illness with a car injury about 2 years ago, when she received a severe bruise on the mammary gland during breastfeeding, as a result of which mastitis occurred. She underwent conservative treatment. I consulted an oncologist in April 2021 about a tumor formation in the left breast. Ultrasound (04/11/2021) of the mammary glands: on the echotomograms of the mammary gland on the left, in the upper and lower outer quadrant, formations 55x44 mm are visualized. heterogeneous structure with uneven edges. In the axillary region, there is a conglomerate of 54x38 mm, a smaller number of lymph nodes. At the branch of the Republican Specialized Scientific Practical Medical Center of Oncology and Radiology (RSSPMCOR), the patient underwent a breast tumor biopsy. The histological conclusion: Ductal carcinoma G-1. Immunohistochemical analysis of the tumor showed no expression for estrogen and progesterone receptors, expression of epidermal growth factor - weak membrane staining of more than 10% of tumor cells (1+). The proliferative activity of the tumor (Ki67) is 40%, no polymorphism of the BRCA 1,2 genes was revealed.

On PET-CT examination in the projection of the upper and lower outer quadrants of the left breast, drainage nodules with hyperfixation of the RFP SULmax = 94 with a thickness of 28x22 mm and a total length of 68 mm are revealed. In the central part of the gland downward from the nipple, a node measuring 15x9 mm is determined, with RPH hyperfixation SULmax = 7.5. The nipple is retracted, with the presence of an RFP hyperfixation area SULmax = 3.6 along the lateral contour. In the axillary and subclavian regions on the left, the presence of metabolically active SULmax = 9.7 lymph nodes is noted, with a thickness of up to 25 mm along the short axis. The intrathoracic lymph node is visualized parasternally on the left, measuring 15x9 mm, with RPH hyperfixation SULmax = 4.9.

Status Localis. The left mammary gland is edematous. Skin with signs of lemon peel. The nipple is retracted. In the left upper and lower-outer quadrants, a tumor is palpable up to 6.0 cm in diameter, dense, painful to the touch. In the axillary region on the right, a large conglomerate of lymph nodes up to 6.0 cm in diameter is palpable.

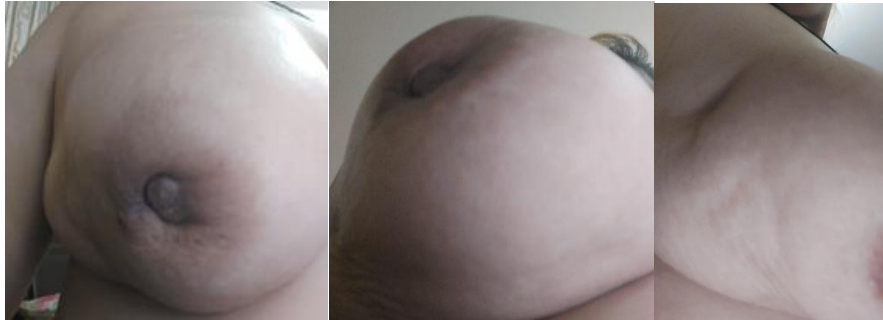

Figure # 1. Photo of the left breast with deformation of the contours of the gland, with an inverted nipple and the presence of a tumor conglomerate in the axillary region.

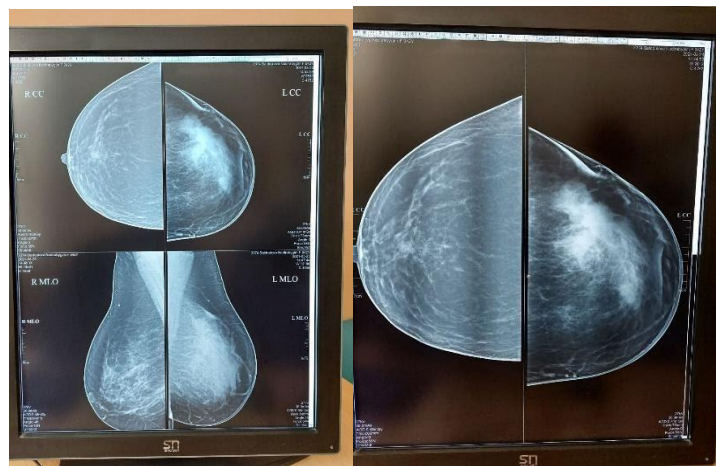


Figure # 2. X-ray mammogram of the breast.

The patient was further examined, an immunogram of blood and functional studies of the body systems were performed. a clinical diagnosis was made: three times negative cancer of the left breast, edematous-infiltrative form T3N1M0.

Her doctors decided to conduct accompanying therapy according to the original scheme, which includes several positions.

First stage: Course with non-specific correction of the immune system. As an apparatus for nonspecific immunocorrection, the Therapeutic Apparatus "TOP-Technology of Operative Rehabilitation" was used, which acts on the immune cells of the human body with an alternating magnetic field in the medium frequency range of 350 KHz, at a wavelength of 857 meters and with an impact energy of 16 V. In immunological experiments, it was found that when exposed to a given alternating magnetic field, the number of T-lymphocytes and CD16 NK cells increases significantly.

At the same time, the patient took an oral immunomodulatory drug (the main active ingredient is tissue hydrolyzate) "RCV" (Uzbekistan) in a daily dose of 1600 mg for 15 days. It has been shown that this drug activates the cytotoxic functions of macrophages (i.e., it is likely that reprogramming from M2 to M1), intensely enhances the synthesis of IFN $\gamma$  and increases the number of active CD-4 and CD8 T-lymphocytes.

The second stage is aimed at the destruction of the tumor. In this capacity, chemotherapy was chosen, which included 8 courses (once every 3 weeks) according to the AC scheme (doxorubicin + cyclophosphamide). A characteristic and distinctive point is that the first 3 doses of the AU scheme in the full dose, in subsequent infusions, the dose of drugs (doxorubicin + cyclophosphamide) gradually decreased to 25%. With this approach, low-dose chemotherapy can be carried out for a sufficiently long time. Clinical and laboratory monitoring of the patient's condition was periodically carried out.

The third stage: before the end of the course of chemotherapy (for 7 days) the patient took drugs that suppress the explosive growth of tumor cells - "Ablast" (Uzbekistan), 1 capsule 2 times a day, "Aspirin" 1 g in a daily dose and selenium preparations. This stage lasted 15 days. The fourth stage is the recovery stage. The patient was prescribed adaptogens (Ren-Sheng preparations) and vitamin D3 and a short course of therapy with the TOP technology according to the algorithm. After 4.5 months from the moment of concomitant therapy, which included all of the above stages and low-dose chemotherapy, complete elimination of the tumor process in the mammary gland was achieved.

Control studies in September 2021: ultrasound (from 09/07/2021) on echotomograms of the mammary glands and regional lymph nodes did not reveal pathological formations. (see figure # 3)

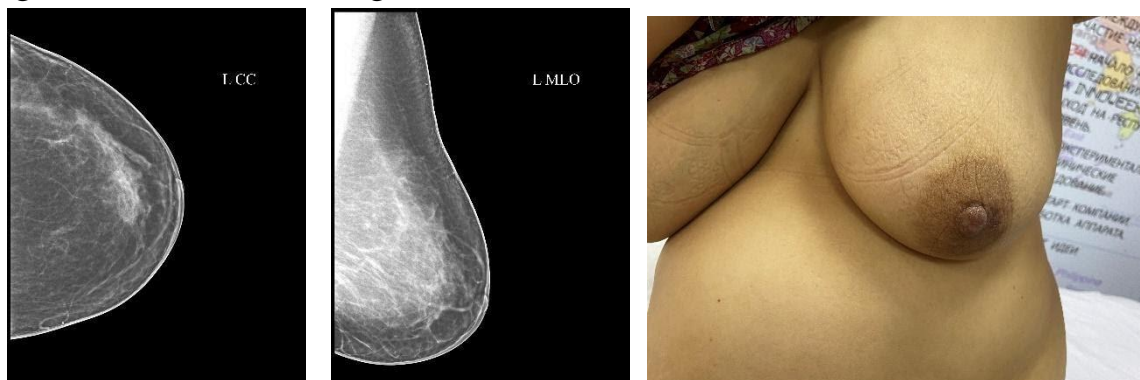

Figure # 3. Dynamics of the X-ray mammogram of the left breast and a photo of the patient N. S. in September 2021.

During clinical examination and palpation in the mammary gland, pathological changes were not determined. In order to prevent relapse, therapy

with Ginseng was continued. Currently, the patient is active, according to the Karnofsky scale of 90%.

#### **DISCUSSION OF THE CLINICAL CASE**

The course of treatment performed showed very good, positive dynamics and was rather easily tolerated by the patient. There are likely a multitude of reasons for this. First, the patient's body was prepared for the toxic effects of cytostatics. The physiotherapeutic and medical methods of immunocorrection utilized not only pre-activated the functions of various factors of the immune system, but also increased the general resistance of the body to the effects of various toxins, including toxic products of cell decay, which occurred under the influence of chemotherapy. In future cases, the decay products of tumor cells should probably be given special attention, since this process causes a strong antigenic attack on the body.

In conditions of functionally weakened cells of the immune system (especially macrophages, dendritic and NK cells, cytotoxic T-lymphocytes, etc.), which is usually observed in oncology, massive antigenic exposure easily leads to its overload and induction of high-dose tolerance. Of course, this all facilitates the explosive, recurrent tumor growth, which is often observed after the final phases of oncolytic therapy, including chemotherapy, radiotherapy, surgical exposure, etc. complex with their damaged structures, which are perceived as immunoactivating patterns (DAMP), then the antitumor immunity in the body will only increase.

This can not only help in the destruction of the main tumor, but also affect small metastases, if any. Second, a combined chemotherapy regimen was used in this case. We expected that the first doses of chemotherapy would be most effective in destroying the tumor. Therefore, the first three doses were administered in full. In the future, the effectiveness of injections of cytotoxic agents decreases, and their toxic effect on the body increases. As a result, the patient was recommended to reduce the dosage and transfer it to low-dose therapy. This approach made it possible to achieve the destruction of the tumor, on one hand, and the preservation of good health and physiological parameters in the patient, on the other. We believe that a decrease in oncolytic, therapeutic doses, especially in conditions of adequate immunocorrection, has certain prospects. Thirdly, in this case, after a course of chemotherapy, a stage was used when the patient took drugs that block the recurrent growth of possibly remaining tumor cells and maintain antitumor immunity. This also probably played a role. However, the follow-up period is still very short and the corresponding conclusions can be drawn only in a few years, when stable remission is confirmed. In general, the description of this clinical experience may be interesting in terms of some new

approaches to the management of patients with cancer. Thus, the proposed method demonstrates its sufficient efficiency and ease of implementation.

## REFERENCES

1. Dent R, Trudeau M, Pritchard KI, Hanna WM, Kahn HK, Sawka CA, et al. Triple-negative breast cancer: clinical features and patterns of recurrence. *Clin Cancer Res.* 2007 Aug 1;13(15 Pt 1):4429-4434. <https://doi.org/10.1158/1078-0432.CCR-06-3045>
2. Foulkes WD, Smith IE, Reis-Filho JS. Triple-negative breast cancer. *N Engl J Med.* 2010 Nov 11;363(20):1938-1948. <https://doi.org/10.1056/NEJMra1001389>
3. Foulkes WD, Smith IE, Reis-Filho JS. Triple-negative breast cancer. *N Engl J Med.* 2010 Nov 11;363(20):1938-1948. <https://doi.org/10.1056/NEJMra1001389>  
<https://doi.org/10.3747/co.25.3954>
4. Lebert JM, Lester R, Powell E, Seal M, McCarthy J. Advances in the systemic treatment of triple-negative breast cancer. *Curr Oncol.* 2018 Jun;25(Suppl 1):S142-S150.
5. Siegel RL, Miller KD, Jemal A. Cancer Statistics, 2017. *CA Cancer J Clin.* 2017 Jan;67(1):7-30. <https://doi.org/10.3322/caac.21387>
6. Astashov V.V., Volkova M.S., Kazakov O.V., Ivanova Ye.B., Larionov P.M., Chepik V.I. i dr. Regionarnoye limfaticeskoye ruslo pri eksperimental'noy induktsii opukholi molochnoy zhelezy v usloviyakh profilakticheskoy fitoterapii. Zhizn' bez opasnostey. *Zdorov'ye. Profilaktika. Dolgoletiyе.* 2012;7(2):109-115. Astashov V.V., Volkova M.S., Kazakov O.V., Ivanova E.B., Larionov P.M., Chepik V.I. Regional lymphatic bed during experimental induction of a breast tumor under conditions of prophylactic phytotherapy. *Life without danger. Health. Prevention. Longevity.* 2012;7(2):109-115.
7. Vladimirova L.Yu., Storozhakova A.E., Snejko T.A., Strakhova L.K., Abramova N.A., Kabanov S.N. Hormone-positive HER2-negative metastatic breast cancer: decision making in real clinical practice. *South Russian journal of oncology.* 2020;1(2):46-51. <https://doi.org/10.37748/2687-0533-2020-1-2-6>. Vladimirova L.YU., Storozhakova A.E., Snezhko T.A., Strakhova L.K., Abramova N.A., Kabanov S.N. i dr. Gormonopolozhitel'nyy HER2-negativnyy metastaticheskiiy rak molochnoy zhelezy: prinyatiye resheniy v real'noy klinicheskoy praktike. *Yuzhno-rossiyskiy onkologicheskiiy zhurnal.* 2020;1(2):46-51. <https://doi.org/10.37748/2687-0533-2020-1-2-6>
8. Ignatov P.E., Sabirov D.R. Substantiation of new approaches to the therapy of oncological diseases., *Journal of Hospital Medicine: Science and Practice;* Volume 4, No. 3, 2021, 45-47. Ignatov P.Ye., Sabirov D.R. Obosnovaniye novykh

podkhodov k terapii onkologicheskikh zabolevaniy., Zhurnal Gospital'naya meditsina: nauka i praktika; tom 4, №3, 2021, 45-47.

9. Roitberg G.E., Kondratova N.V. Screening and prevention of breast cancer in the work of a primary care physician. Bulletin of Roszdravnadzor. 2018;(1):57-61. Roytberg G.Ye., Kondratova N.V. Skrining i profilaktika raka molochnoy zhelezy v rabote vracha pervichnogo zvena. Vestnik Roszdravnadzora. 2018;(1):57-61.

10. Roitberg G.E., Dorosh J.V., Anikeeva O.Yu. Treatment of triple negative breast cancer in a patient with metabolic syndrome. Research'n Practical Medicine Journal. 2021;8(1):62-68. Roytberg G.Ye., Dorosh ZH.V., Anikeyeva O.YU. Lecheniye trizhdy negativnogo raka molochnyy zhelezy u patsiyentki s metabolicheskim sindromom. Research'n Practical Medicine Journal. 2021;8(1):62-68.

11. Ruziev K.I., Sabirov D.R. An innovative non-invasive method in the treatment of oncological diseases using the technology of surgical treatment., Journal of Science and Innovative Development; 2020, No. 05., pp. 27-33. Ruziyev K.I., Sabirov D.R. Innovatsionnyy neinvazivnyy metod v lechenii onkologicheskikh zabolevaniy s primeneniym tekhnologii operativnogo lecheniya., Zhurnal Nauka i innovatsionnoye razvitiye; 2020, №05., str. 27-33