

TREATMENT OF ACUTE EROSIVE-ULCERATIVE GASTRODUODENAL BLEEDING

M.Sh. Khakimov, U.I. Matkuliev, Sh.E. Ashurov, O.T. Sattarov,
J.K. Dekhkonov

Tashkent Medical Academy, Uzbekistan

ABSTRACT

To date, the tactics of treating patients with acute erosive-ulcerative gastroduodenal bleeding remains one of the most actual problem of urgent surgery. According to various authors, acute erosion and ulcers of the mucous membrane of the gastroduodenal zone are detected about 5-10% during endoscopic examination [1, 2]. In most published works, bleeding from acute ulcers is often treated as a peptic ulcer, using the same therapeutic and tactical techniques. The clinical course of acute ulcers differs from the manifestations of peptic ulcer. **Material and methods:** We analyzed 215 clinical cases with acute erosive-ulcerative bleeding, which were received by the emergency surgery department of the clinic of the Tashkent Medical Academy for the period from 2014 to 2021 yy. The age of patients ranged from 18 to 83 years. **Results and discussion:** Among patients undergoing endoscopic manipulations, the final hemostasis was achieved in 53 (88.3%) cases. Recurrence bleeding was noted in 7 (11.7%) cases. After repeated endoscopic intervention in 3 cases, the bleeding was finally stopped. 4 (1.9%) patients, due to the inefficiency of endoscopic methods of hemostasis in an extremely serious condition, were taken for surgery ongoing bleeding. **Conclusions:** Endoscopic methods of hemostasis are effective for bleeding (especially F-I-A, F-I-B, F-II-A degrees) from acute ulcers and erosion of the upper gastrointestinal tract, with the frequency of final hemostasis up to 93.3%; The use of combined methods and retrograde hemostasis in the position on the “right side” made it possible to stop bleeding in 90% of cases; With the ineffectiveness of endoscopic methods, it is necessary to resort to open surgery.

Key words: hemostasis, acute ulcers, arterial bleeding, vomiting, pain.

INTRODUCTION

To date, the tactics of treating patients with acute erosive-ulcerative gastroduodenal bleeding remains one of the most actual problem of urgent surgery. According to various authors, acute erosion and ulcers of the mucous membrane of the gastroduodenal zone are detected about 5-10% during endoscopic examination [1, 2]. However, the actual frequency of gastroduodenal erosive-ulcerative processes has not yet been established. They are often found when patients are

examined for dyspeptic symptoms, but more often – with the appearance of complications such as bleeding (in 60–70% of cases) or perforation (in 0.5–3% of cases) [3]. The etiological factors of acute erosion and ulcers complicated by bleeding are injuries, burns and surgical interventions [4]. Cases of erosion and ulcers of the upper gastrointestinal tract after significant operations in patients who previously did not suffer from gastrointestinal tract diseases are described. Mortality in this category of patients, especially with severe concomitant pathologies, can reach up to 60%, with a relapse of bleeding this indicator is more than 80% [5, 6].

In most published works, bleeding from acute ulcers is often treated as a peptic ulcer, using the same therapeutic and tactical techniques. The clinical course of acute ulcers differs from the manifestations of peptic ulcer. Uncomplicated acute ulcers in most patients are asymptomatic. The appearance of pain in the epigastric region, nausea, vomiting, and pain during palpation of the anterior abdominal wall may indicate the formation of acute ulcers and erosion of the stomach or intestines. Diagnosis of uncomplicated ulcers presents certain difficulties. Of all the known diagnostic methods, endoscopic examination not only allows you to correctly establish the diagnosis, but also makes it possible to conduct endoscopic hemostasis, the clinical effectiveness of which exceeds 85% [7].

The main reasons for the unsatisfactory results of endoscopic arrest of bleeding are the presence of intense arterial bleeding, which leads to difficulties in visualizing the source of bleeding, the presence of blood disorders, etc.

Material and methods: We analyzed 215 clinical cases with acute erosive-ulcerative bleeding, which were received by the emergency surgery department of the clinic of the Tashkent Medical Academy for the period from 2014 to 2021 yy. The age of patients ranged from 18 to 83 years. Of these, over 65 were over 50.0%. In 157 (73.0%) patients, the cause of bleeding was acute ulcers and erosion of the stomach (antrum and prepyloric part - 117 cases, the body of the stomach - 16, the cardiac part- 7, the bottom of the stomach - 3 and the back wall of the body and a large curvature of the stomach - 14 cases) and 58 (27.0%) had an acute duodenal ulcer. It should be noted that the last location of stomach ulcers is not common, but there are technical difficulties in visualizing these zones of the stomach associated with the location of blood clots over this area during bleeding from the upper gastrointestinal tract. By the intensity of bleeding, all patients were distributed as follows: F-I-A - 7 (3.3%), F-I-B - 19 (8.9%), F-II-A - 34 (15.7%), F-II- B - 135 (62.8%) and F-II-C - 20 (9.3%) observations. (Table. No. 1.)

Table 1.

Distribution of patients by the intensity of bleeding

Stage	Characteristics	Patients	Rebreeding
F-I A	Jet arterial bleeding	7	3.3%
F-I-B	Oozing	19	8.9%
F-II-A	Visible Vessel	34	15.7%
F-II- B	Adherent clot	135	62.8%
F-II-C	Black spot in ulcer crater	20	9.3%

An analysis of the main causes of acute ulcers revealed that in 115 (53.5%) patients, the pathology developed due to uncontrolled administration of non-steroidal and steroidal anti-inflammatory drugs, 72 (33.5%) patients were associated with volume surgeries, car accidents and burns, the rest 28 (13.0%) patients were hospitalized for a long time, and the cause of gastrointestinal hemorrhage (GH) from acute ulcers was a complicated course of the underlying disease or its decompensation. Moreover, in most cases, preventive antiulcer therapy was not carried out.

Most often, acute ulcers were observed in the hospital, appearing against the background of decompensating of some acute and chronic diseases, often associated with multiple organ failure syndrome. Most ulcers in this group occurred with a combination of diseases of the cardiovascular, respiratory system and diabetes mellitus. When analyzing the nature of the concomitant pathology, a significant dependence of the appearance of acute ulcers with the number of systemic organ lesions was found. In 182 (84.5%) patients with concomitant pathology, a combination of two or more diseases was observed, the most frequent manifestations of coronary heart disease, chronic non-specific lung diseases and cerebrovascular disease. In addition, in this group there were 23 patients with decompensated cirrhosis and liver failure and 10 patients with chronic renal failure.

Thus, the risk factors for the development of complications from acute ulcers in this group include: 1. advanced age; 2. limited nutrition, leading to an imbalance in the acid-base balance in the stomach; 3. Uncontrolled intake of steroid and non-steroidal anti-inflammatory drugs; 4. 2-3 degree of organ dysfunction in assessing the severity of APACHE; 5. long bed rest.

Therefore, when these adverse factors are detected in patients, erosive and ulcerative lesions of the gastrointestinal tract should be prevented. Acute ulcers associated with taking medications are observed in 45–68% of elderly patients and recently account for a third of the causes of gastroduodenal bleeding. According to our data, this is the first frequency cause of complications of acute ulcers in inpatients.

For the most part, these ulcers appear after taking cyclooxygenase inhibitors. Among our patients, 115 (53.5%) were over 65 years old, took more than 3 drugs per day, usually disaggregants (analogues of acetylsalicylic acid), anticoagulants (warfarin), NSAIDs (diclofenac, voltaren, ibuprofen) and steroid preparations. Of these, 39 (18.1%) patients had systemic diseases and diabetes mellitus, and they regularly received steroid (prednisone, beclomethasone) and hypoglycemic drugs in combination with anti-inflammatory drugs and antiplatelet agents.

Acute ulcers in the early postoperative period develop in 2.5–24% of patients [8]. Under our supervision, there were 72 (33.5%) patients with acute ulcers in the postoperative period. All acute ulcers in this group manifested on the 4th – 9th day after surgery and were observed in the complicated course of the postoperative period and the progression of organ dysfunction.

According to the conclusion of the Russian Association of Surgical Infection Specialists, 2 variants of acute ulcers in the early postoperative period are distinguished: I - superficial diffuse erosion with a low risk of bleeding; II - deep localized ulcers with a high risk of hemorrhagic complications, the frequency of which in patients in ICU reaches 14%, and mortality in them is 64% [9]. Difficulties in diagnosing acute ulcers and erosion of the stomach are that 60% of patients do not have clinically significant symptoms of bleeding; the disease is hidden and is diagnosed only with the appearance of hemodynamic disorders.

The standard in the diagnosis of erosive and ulcerative lesions of the upper gastrointestinal tract is endoscopy. Usually, acute ulcers of small sizes 5–10 mm in diameter, the shape of the ulcers is round, the edges are smooth, the bottom is not deep, often with a hemorrhagic plaque (Fig. 1, 2). Their multiplicity is characteristic of acute ulcers, a combination of their localization in the stomach and in the duodenum is often observed.

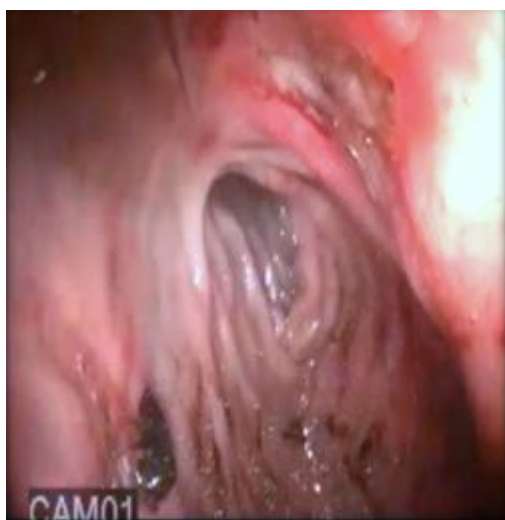

Fig. 1. Acute ulcers of the body of the stomach (the ulcer of the posterior wall is covered with a

fresh thrombus)

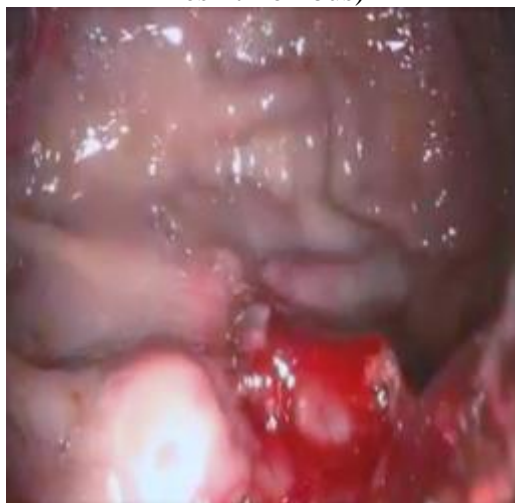

Fig. 2. Acute ulcer of large curvature of the stomach with signs of bleeding (F-I-B)

During an endoscopic examination, in addition to examining the gastroduodenal zone, a primary assessment of the intensity and nature of the bleeding is of particular importance. In order to achieve hemostasis, we used thermal (monopolar, bipolar electrocoagulation, hydrocoagulation, argon plasma coagulation), injection and mechanical (vessel clipping) hemostasis methods. The choice of hemostasis method depended on the intensity of ulcerative bleeding. With bleeding F-II-B and F-II-C, conservative therapy was performed in 155 (72.1%) patients. In 21 cases (9.7%), the edges of the ulcer were chipped, electrocoagulation was performed in 7 (3.3%), argon plasma coagulation in 12 (5.6%), and clipping in 9 (4.2%). In 11 (5.1%) cases, combined methods of endoscopic stopping of bleeding were used (Diagram. No. 1).

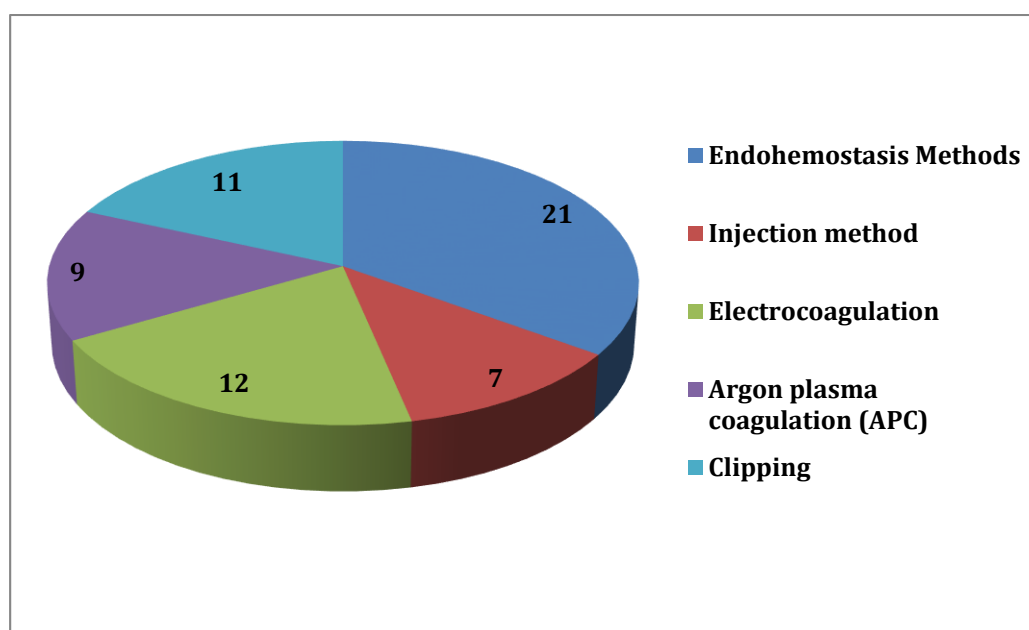


Diagram. No. 1. The applied methods of endoscopic hemostasis

It should be noted that in 14 (6.5%) cases, endoscopic hemostasis was performed for the first time in the position of the patient on the right side with bleeding ulcers of the posterior wall of the upper third of the body and large curvature of the stomach (Figs. 3).

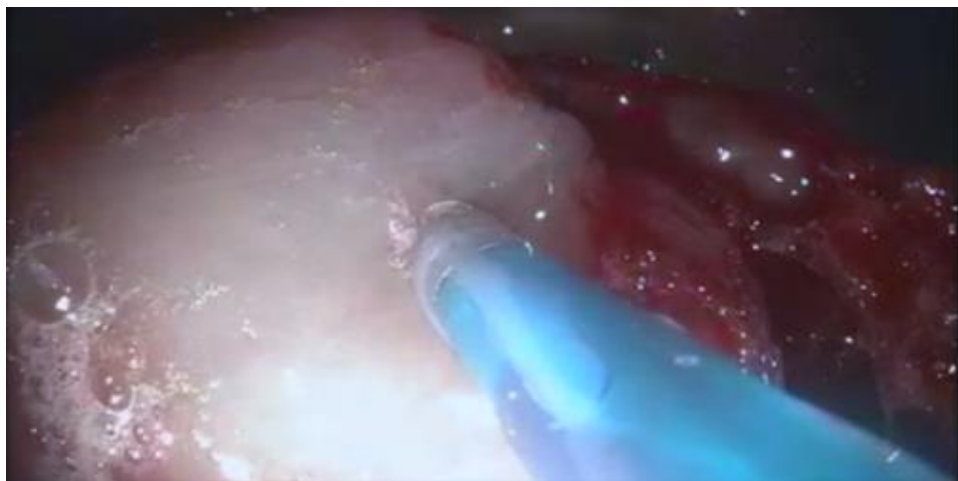


Fig. 3. Acute ulcer of large curvature of the stomach with signs of bleeding (F-I-B). Endoscopic retrograde hemostasis by injection in the "on the right side" position.

Clinical example No. 1. Patient K., 69 years old (IB No. 7822). Received (08/06/2019) in our clinic with signs of profuse bleeding from the gastrointestinal tract. From the anamnesis, the patient suffers from IHD, PICS, diabetes mellitus, type 2 and liver cirrhosis. The patient regularly takes antiplatelet agents, anti-inflammatory drugs.

On EGDS, the esophagus without features in the lumen of the stomach contains blood clots of about 300 ml, the duodenum, the antrum and the body of the stomach without pathology. Upon further retrograde examination, there is an acute ulcer in the upper third of the stomach body from the side of great curvature; however, it is not possible to visualize the size of the ulcer, the nature of the bleeding due to the presence of blood clots over this area. In order to visualize the latter, the patient's position on the right side was changed. After that, all blood clots moved to a small curvature. It was further revealed that there is an acute ulcer in the area of large curvature of the stomach, 10x12 mm in size with signs of active bleeding (Fig. 4.). Performed retrograde endoscopic chipping of the edges of the ulcer with a 33% ethanol solution. Bleeding was stopped. The patient in satisfactory condition was discharged on the 4th day.

After performing endoscopic hemostasis with active bleeding with acute ulcers, it is necessary to identify groups of high and low risk of recurrence according to the Forrest classification. To the groups of high endoscopic risk of

recurrence of bleeding from acute ulcers, we included patients with active bleeding from one or more acute ulcers at the time of primary endoscopy (F-I-A, F-I-B, F-II-A). In patients with bleeding F-II-B, F-II-C, F-III, with a clinical manifestation of bleeding, regardless of the severity of anemia, a low risk of bleeding recurrence was observed.

According to the results of primary gastroscopy in high-risk groups of recurrence of bleeding, a dynamic study is necessary to implement endoscopic prophylaxis of repeated hemorrhage. The term for performing repeated EGDFS depended on the reliability of the performed primary hemostasis and averaged 0.5–3 days from the moment of primary endoscopy. During dynamic EGDFS, the quality of hemostasis, the risk of recurrence of bleeding was reevaluated and its prevention was carried out with a continuing threat. With successful endoscopic hemostasis, further methods of prevention and treatment were intensive antiulcer therapy, normalization of the motor – evacuation function of the stomach, and symptomatic treatment.

Results and discussion: Among patients undergoing endoscopic manipulations, the final hemostasis was achieved in 53 (88.3%) cases. Recurrence bleeding was noted in 7 (11.7%) cases. After repeated endoscopic intervention in 3 cases, the bleeding was finally stopped. 4 (1.9%) patients, due to the inefficiency of endoscopic methods of hemostasis in an extremely serious condition, were taken for surgery ongoing bleeding. The overall mortality rate was 1.4% (3 observations). In the postoperative period, 2 patients died due to multiple organ failure. Another patient died in the early postoperative period due to the development of suture failure, peritonitis and DIC.

According to I.M. Gralnek [10], the use of endoscopic methods of hemostasis in combination with modern antisecretory therapy in most cases of bleeding from acute ulcers can prevent its recurrence and achieve adequate hemostasis without surgery. In general, the effectiveness of endoscopic hemostasis can reach 90–95%. In our observations, recurrence of bleeding in the low-risk group was not observed. In 7 (4.2%) patients at high risk, a recurrence of bleeding was noted. After repeated endoscopic intervention in 3 cases, final hemostasis was achieved.

According to P.W. Elroy [11], using the injection method with the use of a 33% ethanol solution, primary hemostasis was achieved in 90% of patients, the final hemostasis in 85% of patients, the rate of bleeding recurrence was 15%. However, often this method can lead to tissue destruction and massive necrosis of the organ wall with its subsequent perforation, which is the negative side of this method.

In his research E. Wedi [12] claims that the use of coagulation methods of hemostasis allows primary hemostasis to be achieved up to 91-94.0% of cases, final - in 85.0-88.0% of patients, reduces the number of urgent operations to 10.5%, mortality - to 3.0- 4.5%, recurrence of hemorrhage occurs in 8.0-9.5% of patients. In 21 cases, we used coagulation methods (diathermocoagulation - 7, argon-plasma coagulation - 12, combined method - 2). Relapse of hemorrhage was noted in 2 (9.5%) cases, which required surgical treatment.

In 1980, for the first time in Japan, Dr. Hung, together with the company “Olimpus”, created a clipper and clips for endoscopic hemostasis. In his opinion, with the help of endoscopic clipping for ulcerative bleeding, hemostasis is achieved in 85-100% of cases, reducing the frequency of recurrence from 20% to 2% [13].

M.Venerito [14] in Italy, applying the endoclipping technique in 88 patients with active ulcerative bleeding from the upper gastrointestinal tract, obtained an excellent result. Relapse was observed in 5 (5.6%) cases, of which one patient was operated on. There were no fatal cases.

Many authors claim [15, 16] that using rotary clips in patients with active ulcerative bleeding can achieve final hemostasis in 95% of cases, recurrence decreased to 5.0% of cases. Moreover, the inefficiency of the method may be associated with technical difficulties in visualization and from the location of the bleeding source. We used endoscopic clipping in 12 patients, of which in 3 cases they were combined with other methods. Bleeding recurrence was noted in 2 (16.6%) cases, in one of them it was possible to stop bleeding endoscopically, in the other - surgical treatment was required.

A randomized study was published in the journal “Gastrointestinal endoscopy”, which reported that the frequency of primary final hemostasis during endoclipping increased from 92 to 96%, and the number of bleeding recurrences decreased by almost 2 times (from 15 to 8.5%). However, a change in the method of endoscopic hemostasis did not affect mortality rates and open surgical interventions [17].

Such a considerable difference in indicators of persistent hemostasis or relapse of bleeding is mainly due to the “difficult” location of the source of bleeding and profuse arterial bleeding. Despite the advantage of modern endoscopic methods of hemostasis, further research is needed to develop more effective methods.

Conclusions

1. Endoscopic methods of hemostasis are effective for bleeding (especially F-I-A, F-I-B, F-II-A degrees) from acute ulcers and erosion of the upper gastrointestinal tract, with the frequency of final hemostasis up to 93.3%.

2. The use of combined methods and retrograde hemostasis in the position on the “right side” made it possible to stop bleeding in 90% of cases.

3. With the ineffectiveness of endoscopic methods, it is necessary to resort to open surgery.

REFERENCES

1. Scally B., Emberson J.R., Spata E., et al. Effects of gastroprotectant drugs for the prevention and treatment of peptic ulcer disease and its complications: a meta-analysis of randomised trials // *Lancet Gastroenterol Hepatol.* 2018;3(4):231–241.

2. Katrine K.R., Trond E.D., Taran S., et al. Treatment and outcome of gastrointestinal bleeding due to peptic ulcers and erosions – (BLUE study) // *Scandinavian journal of gastroenterology* 2022, vol. 57, No. 1, 8-15 <https://doi.org/10.1080/00365521.2021.1988701>

3. Knuuti J., Wijns W., Saraste A., et al. 2019 ESC guidelines for the diagnosis and management of chronic coronary syndromes // *Eur Heart J.* 2020;41(3):407–477.

4. Sarri G.L., Grigg S.E., Yeomans N.D. Helicobacter pylori and low-dose aspirin ulcer risk: a meta-analysis // *J.Gastroenterol Hepatol.* 2019;34(3):517–525.

5. Faisal K., Muhammad A., Wade L., et al. Efficacy and safety of tranexamic acid in acute upper gastrointestinal bleeding: meta-analysis of randomised controlled trials // *Scandinavian Journal of Gastroenterology*, Volume 55, 2020 - Issue 12

6. Sverden E., Brusselaers N., Wahlin K., et al. Time latencies of Helicobacter pylori eradication after peptic ulcer and risk of recurrent ulcer, ulcer adverse events, and gastric cancer: a population-based cohort study // *Gastrointest Endosc.* 2018;88(2):242–250e1.

7. Malfertheiner P., Megraud F., O'Morain C.A., et al. Management of Helicobacter pylori infection - the Maastricht V/Florence Consensus // *Report. Gut.* 2017;66(1):6–30.

8. Barkun A.N., Almadi M., Kuipers E.J., et al. Management of nonvariceal upper gastrointestinal bleeding: guideline recommendations from the International Consensus Group // *Ann. Intern. Med.* 2019;171(11):805–822.

9. Vítor M., Silva M., Cátia A. et al. Direct oral anticoagulants are associated with potentially bleeding lesions in suspected mid-gastrointestinal bleeding // *Scandinavian Journal of Gastroenterology* Published online: 11 Dec 2021 <https://doi.org/10.1080/00365521.2021.2014951>

10. Gralnek I.M., Dumonceau J.M., Kuipers E.J., et al. Diagnosis and management of nonvariceal upper gastrointestinal hemorrhage: European Society of Gastrointestinal Endoscopy (ESGE) Guideline. // *Endoscopy.* 2019;47(10):a1–a46.

11. Elroy P.W. Acute upper gastrointestinal bleeding: A review. // *Surgery in Practice and Science.* 2020; N1 (100004):P 1-7

12. Wedi E., Fischer A., Hochberger J., Jung C., Orkut S., Richter-Schrag H.J. Multicenter evaluation of first-line endoscopic treatment with the OTSC in acute non-variceal upper gastrointestinal bleeding and comparison with the Rockall cohort: the FLETRock study // *Surg Endosc.* 2018;32:307–14.

13. Hung K.W., Knotts R.M., Faye A.S., et al. Factors associated with adherence to *Helicobacter pylori* testing during hospitalization for bleeding peptic ulcer disease // *Clin Gastroenterol Hepatol.* 2020;18(5):1091–1098.e1.

14. Venerito M., Schneider C., Costanzo R., et al. Contribution of *Helicobacter pylori* infection to the risk of peptic ulcer bleeding in patients on nonsteroidal anti-inflammatory drugs, antiplatelet agents, anticoagulants, corticosteroids and selective serotonin reuptake inhibitors // *Aliment Pharmacol Ther.* 2018;47(11):1464–1471.

15. Hooi J.K.Y., Lai W.Y., Ng W.K., et al. Global prevalence of *Helicobacter pylori* infection: systematic review and meta-analysis // *Gastroenterology.* 2017;153(2):420–429.

16. Lin K.J., García Rodríguez L.A., Hernández-Díaz S. Systematic review of peptic ulcer disease incidence rates: do studies without validation provide reliable estimates // *Pharmacoepidemiol Drug Saf.* 2021;20(7):718–728.

17. Omero A., Paoluzi C., Antonio A., et al. Efficacy of hemostatic powders as monotherapy or rescue therapy in gastrointestinal bleeding related to neoplastic or non-neoplastic lesions // *Scandinavian Journal of Gastroenterology*, Volume 56, 2021 - Issue 12.