

RELATIONSHIP BETWEEN RADIOLOGICAL ANATOMY OF THE STOMACH AND SOMATOTYPE

Dilshod K. Khudoiberdiev

Associate Professor, Ph.D. of the Department of Nuclear Medicine and Medical Radiology of the Bukhara State Medical Institute, Bukhara, Uzbekistan
E-mail: dilshod.khudoyberdiev@mail.ru

ABSTRACT

According to statistics, as of January 1, 2022, one of the highest rates of diseases diagnosed for the first time in the population is associated with diseases of the digestive system, and it is observed that the number of these diseases has reached 11 thousand per 100 thousand of the population. Chronic gastritis accounts for 60-85% of stomach diseases and increases by 1.4% annually. In European countries, 2-5% of the adult population suffers from gastric ulcer. If you look at the studies conducted by scientists, it was noted that ulcers and changes in the wall of the stomach and duodenum account for 8-10% of the total number of biopsies, and sometimes 20%. To date, acute erosions of the mucous membrane are detected in 3-9 percent of patients with this disease during examination, and this condition is considered one of the aspects of diagnosis that requires special attention.

Purpose of the work. A detailed study of digestive tract diseases requires the development of individual preventive and treatment measures for each patient, especially in childhood, it is necessary to pay attention to the structure of the mucous membrane of the digestive system wall. Currently, methods of radiation diagnostics and prognosis are being improved, this method is high-quality, does not cause difficulties and does not cause secondary diseases in the patient.

Key words: Chronic gastritis, gastric ulcer, acute erosions, gastrointestinal tract diseases, X-ray diagnostics.

INTRODUCTION

The urgency of the problem. One of the distinctive features of modern radiology is the high degree of differentiation of organs. Despite numerous studies devoted to the age-related constitutional features of men and women, insufficient attention has been paid to the stomach as a specific morphological constitution at the organ level [7,8].

The human constitutional type can be considered as a combination of physical characteristics, psychodynamics and other features reflecting the state of reactivity

[10]. In medical morphology, the constitution is the main characteristic of the whole organism, fully embodying the idea of the qualitative unity of its biological organization [11].

Different age periods of human life have their own morphological, metabolic and functional characteristics, which determine the difference in the body's response to the same environmental influences. The main features of the structure, metabolism and functions in healthy and sick people are characteristic of the periods of intrauterine development (embryo, fetus) and various stages of extrauterine life of the body (newborns, childhood, etc.) [2].

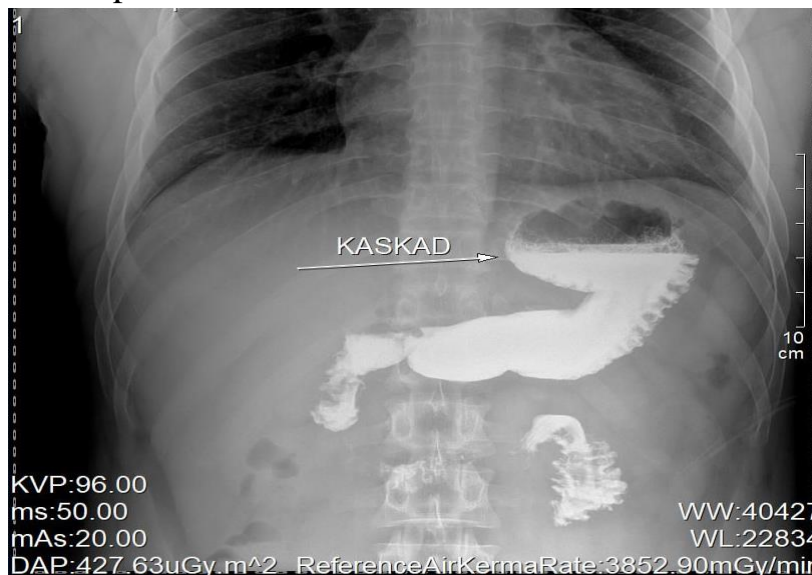Within the framework of the morphological approach, taking into account the constitutional features of the body is an integral component in the study of human health in normal conditions and in various pathologies. This approach to the study of the human body allows not only to gain a more complete understanding of the diversity of age-related typologies and the variability of systems, but also to identify patterns between the somatic constitution of a person and his other systems [5,10,12]. According to the data presented by V.P. Chtesova and her colleagues in the journal "Voprosy antropologii" in 1978, a method was developed for dividing men into 5 somatotypes, women into 7 somatotypes.

It has been established that the somatotypical relationship also affects the degree of destructive and degenerative changes in the spine detected on radiographs. For the thoracic and muscular somatotypes, a mild degree of clinical manifestations is characteristic, while for the abdominal somatotype, on the contrary, pronounced radiological changes in the spine may occur in the clinical picture. It follows that for men with degenerative-dystrophic diseases of the spine, it is necessary to take measures to correct body weight and prevent obesity [6,9].

№	Men	Women
1	Asthenic type	Asthenic type
2	Thoracic type	Stenoplastic type
3	Muscle type	Picnic type
4	Abdominal type	Mesoplastic type
5	Eurysome type	Euryplastic type
6	-	Subathletic type
7	-	Athletic type

X-rays are used to examine the internal organs of the human body, study its structure, movement, and diagnose diseases. Clinical cases encountered in our study were used.

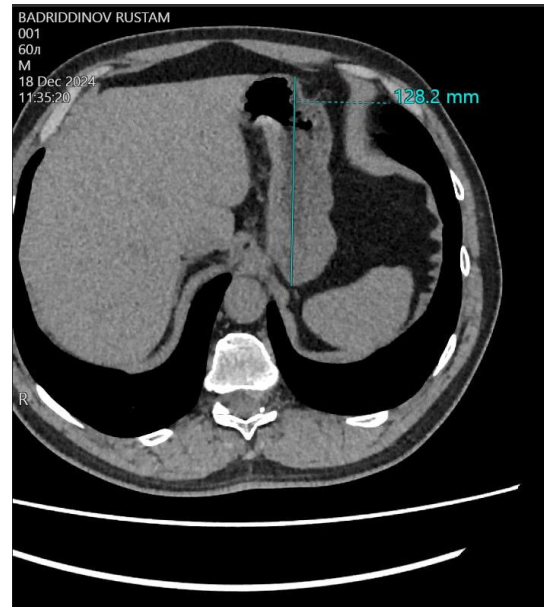
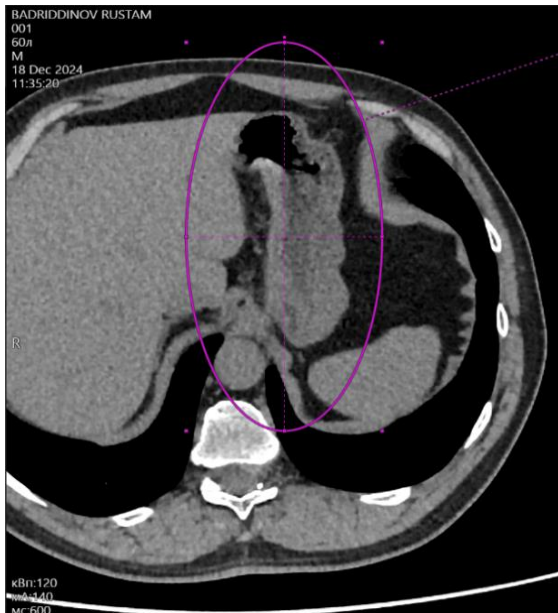
Radiological examinations play an important role in obtaining images of human organs. The organ can be performed using contrast and non-contrast X-ray methods. Optimal radiological diagnostic methods have been developed for each organ of the digestive system. Based on anamnestic and clinical data, a radiological examination is planned and performed. X-ray images allow us to draw conclusions by examining the folds of the gastric mucosa, the spaces between the folds, and the stomach area. All of the above examinations were performed in all of the above patients. Depending on peristalsis, deep, segmental, medium, and superficial peristalsis or the absence of peristalsis are distinguished. The evacuation of the ingested barium enema from the stomach should occur within the first 30 minutes. Complete evacuation from the stomach occurs within 1.5 hours.



Patient Sh.A. was born in 1999. The general explanatory radiograph of this patient revealed signs of a cascade stomach, hypertrophic gastritis.

Common diseases of the stomach and duodenum: 1) acute and chronic gastritis, duodenitis (usually superficial and catarrhal, less often hyperplastic or atrophic, increased acidity of gastric juice, etc.); 2) duodenogastric reflux; 3) erosion of the stomach and duodenum (acute, chronic, cicatricial) and other pre-ulcer conditions; 4) gastric ulcer, symptomatic ulcers of the stomach and duodenum; 5) gastric polyps, among others. In gastrointestinal tract pathologies, diseases of the digestive tract are detected through MSCT examination, and the results obtained are analyzed together with gastroenterologists.

It has been observed that the human somatotypological relationship also affects the degree of changes in the digestive system detected by radiography. For the thoracic type and muscular types, a mild degree of clinical manifestations is characteristic, while for the abdominal type, radiological changes in the stomach and duodenum are characteristic. Therefore, it is recommended that people with diseases of the gastrointestinal tract take measures to correct body weight and prevent obesity.



Patient K.O. Born in 1968. The appearance of the stomach in a horizontal cross-section on MSCT

Conclusion. The constitutional type is an integral feature of the body, which allows for the provision of all forms of human pathology and possible diseases.

Many studies have been carried out showing the constitutional status of vital activity parameters, and genetic-constitutional factors are important in the development of diseases of the digestive system.

REFERENCES

1. Abdulkhakova D. A., Abdulkhakov R. A. X-ray diagnostics of esophageal and gastric diverticula // Vestnik Surgut. Meditsina. – 2022. – №. 3 (53). – С. 40-45.
2. Bukanaeva N.S., Nikityuk D.B. Constitutional features of patients with alimentary-dependent pathology // Morphological Gazette. – 2008. – № 1-2. – С. 145-146.
3. Kobiashvili, M. G. Diagnostics of precancerous changes in the gastric mucosa by narrow-band endoscopy with magnification function / M. G.

Kobiashvili, I. A. Mikhailova, V. N. Ellinidi, I. A. Samusenko // Medical-biological and social-psychological problems of safety in emergency situations. – 2012. – №1. – С. 62-65.

4. Kurilovich, S. A. Non-invasive diagnostics of precancerous diseases of the stomach / S. A. Kurilovich, O. V. Reshetnikov, S. A. Krotov, A. V. Belkoves // Novosibirsk. – 2013. – С.65.

5. Lisnyak E.A. Frequency of detection of radiological stages and degrees of functional insufficiency in women with rheumatoid arthritis of various constitutions and body types // Actual problems of morphology: Collection of scientific papers, Issue 7. – Krasnoyarsk, 2008. – С. 64-66.

6. Nafikova A.Sh. Quality of life in patients with gastric and duodenal ulcers/ A.Sh. Nafikova, L.V. Volevach, A.Ya. Kryukova, G.Ya. Khismatullina, A.A. Kamalova. – Ufa: BSMMU Publishing House, 2016

7. Pervushin V.V., Masalova A.V., Derkach A.A. Constitution and its role in pathology. Classification of constitutional types. The concept of diathesis // International Student Scientific Bulletin. – 2020. – № 6.

8. Sun Q., Liang X., Zheng Q. et al. High Efficacy of 14-Day Triple Therapy-Based, Bismuth-Containing Quadruple Therapy for Initial Helicobacter pylori Eradication // Helicobacter. – 2010. – Vol. 15. – P. 233–238.

9. Vlasov P. V., Blinchevsky I. D., Troshin A. V. X-ray diagnostics of gastric and duodenal ulcers // Medical visualization. – 2006. – №. 2. – С. 19-36.

10. Vlasov P. V., Yakimenko V. F. X-ray diagnostics of gastric cancer at the present stage // Medical visualization. – 2006. – №. 3. – С. 45-59.

11. Yamaoka I. Mechanisms of disease: Helicobacter pylori virulence factor // Nature Reviews Gastroenterology & Hepatology. - 2010. - N7(11). - P. 629-641.

12. Zhin I.G. X-ray method for diagnosing GERD in children // Collection of materials of the Republican Scientific and Practical Conference. Laboratory of Intelligence. - 2018. - 23 ноября. С. 25-33.

13. Zueva E.G., Kudryashov E.V., Dergousova E.N. Clinical and constitutional approaches to assessing the development of spinal deformity // Morphology. – 2008. – № 3. – С. 47.